

**Confidence is good; is control better?**  
State-of-the-art High-tech  
Scientifically explored and tested for effectiveness

Uwe Paasch

University Clinic Leipzig AöR

Clinic for Dermatology, Venereology and Allergology

Convention: Dermatology Clinic, Frankenthal

# JetPeel Hydroporation devices



# Concepts

## Jet

- nozzle
- liquid jet

## Stream

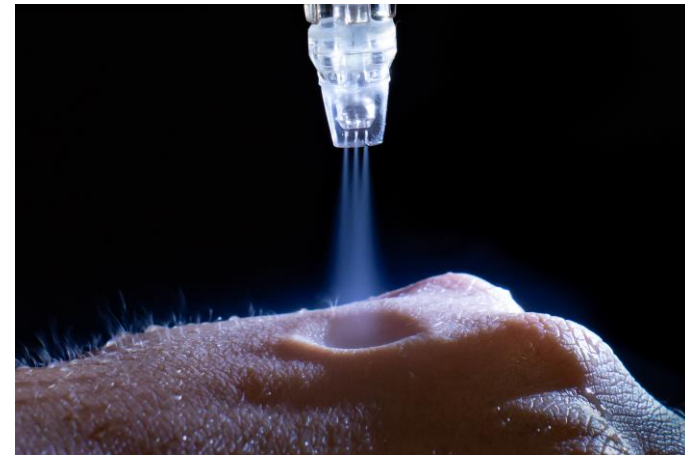- jet
- flow
- stream

## Jetstream


- Jetstream

## JetPeel

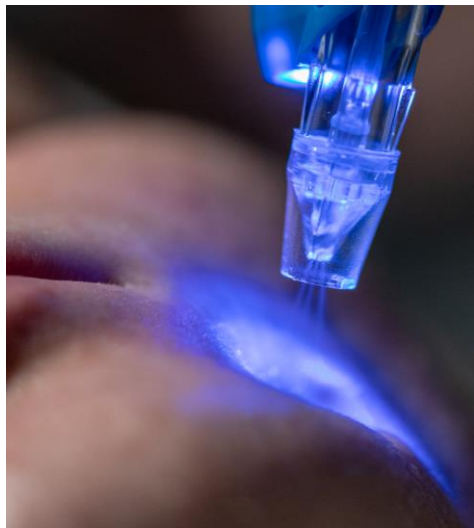
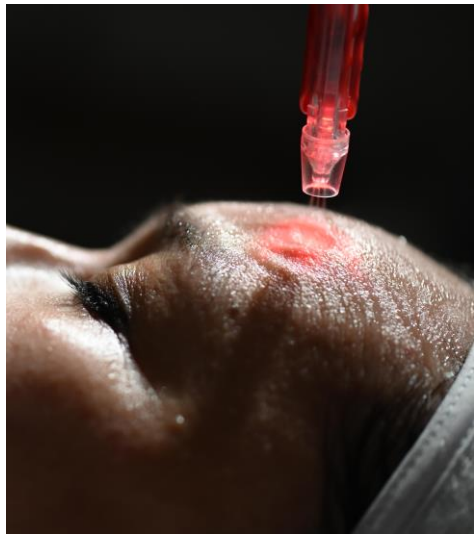
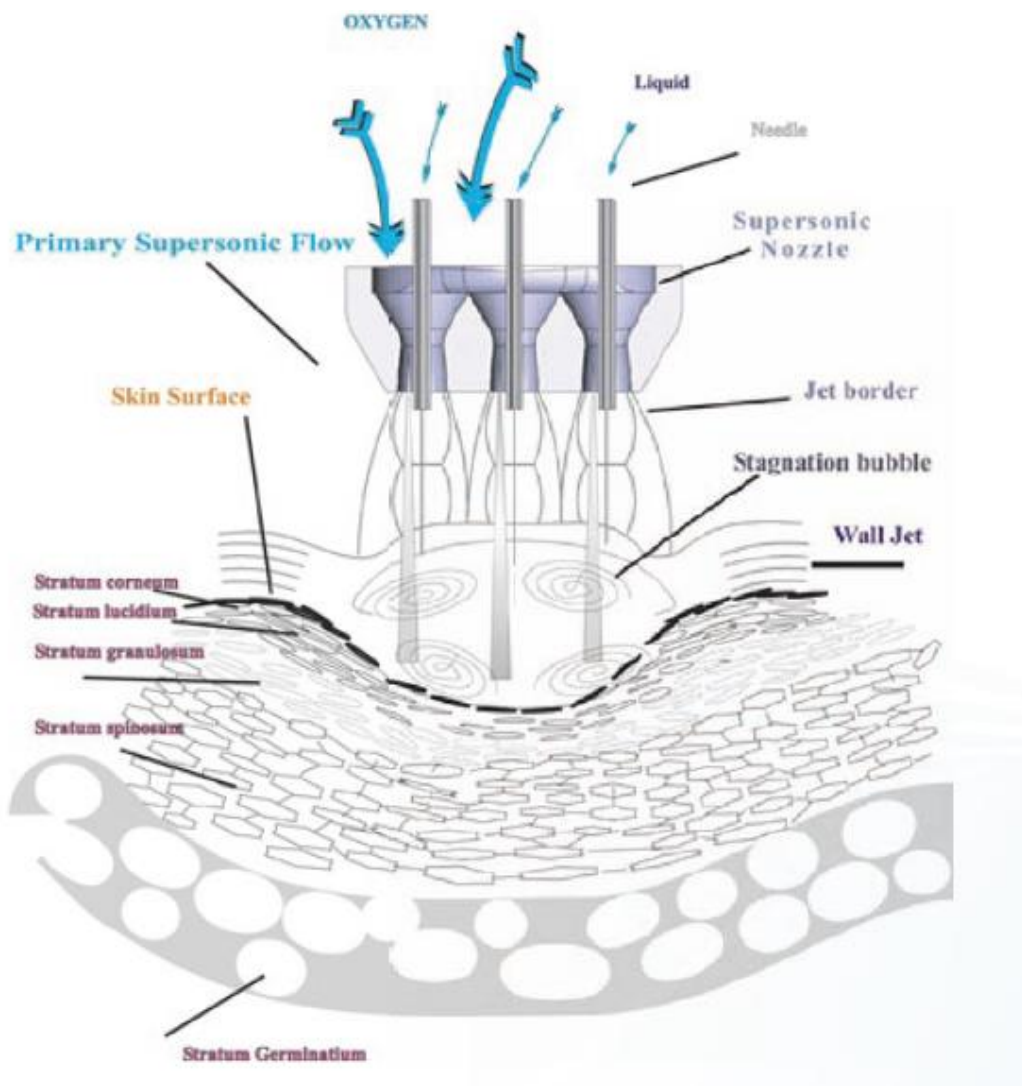
- Original application in surgery
- Transposition into esthetics
- Exploration for dermatology



# Substances: JetCare Serums & JetPeel Handpieces



# Active principle



TavTech, Israel

# Potential fields of application

## Hydropressure

- Massage
- Lymph drainage
  - Rosacea

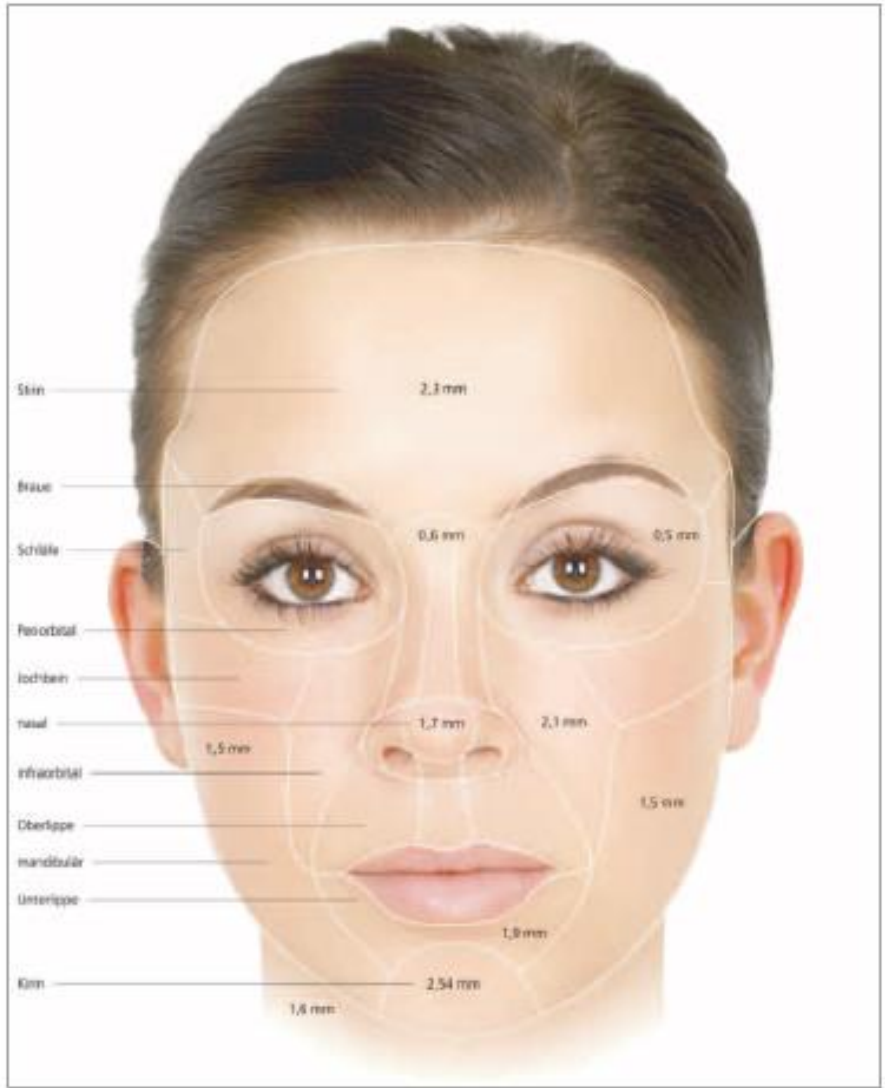
## Hydroabrasion

- Exfoliation / wound cleansing
- Facial cleansing
- Comedolysis
  - Acne

## Hydroporation

- Hyaluronic acid
- Vitamin A, C, B5
- Glycolic acid
- Triamcinolone
- Local anesthetics
- Macromolecules

# Skin thickness and sensitive face areas



**Fig. 3.1** Certain face areas are more sensitive than others to the effects of laser energy, which should be adjusted accordingly. These are, especially, thin skin areas or areas situated immediately above osseous and cartilaginous structures or teeth.

Abb. 6.4 Ästhetische Zonen mit Angaben der ungefähren Hautdicke verändert nach [175, 210], die intraindividuell natürlich starken Schwankungen unterliegt und daher nur als Orientierung dienen kann.

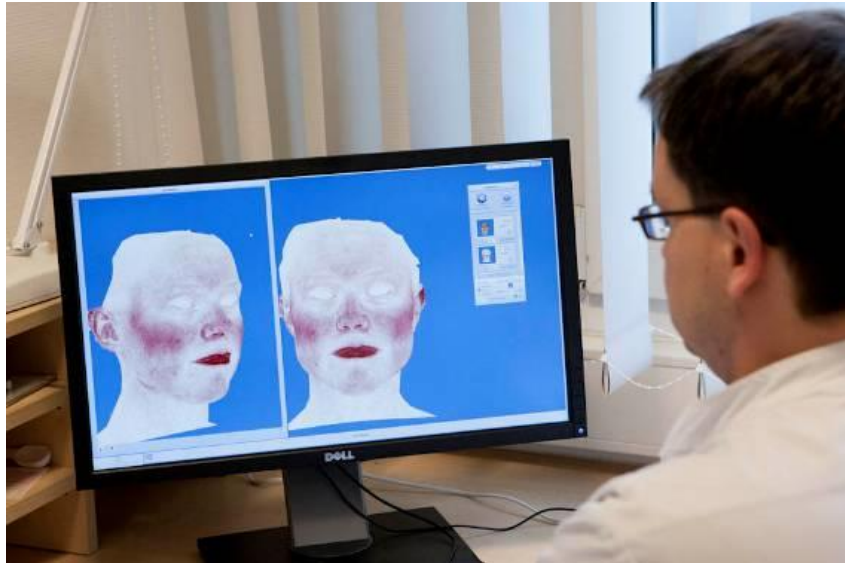## Pilot study for the safety, efficiency and potential implementation possibilities of hydroabrasion and fractional hydroporation in dermatology

### Read out and development parameters

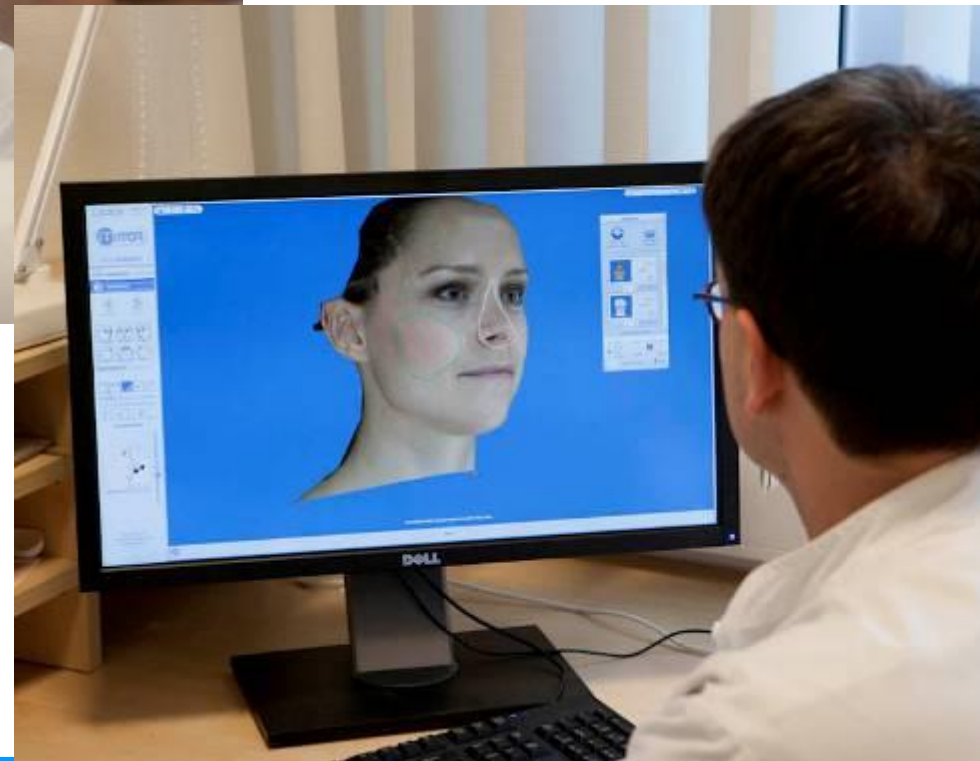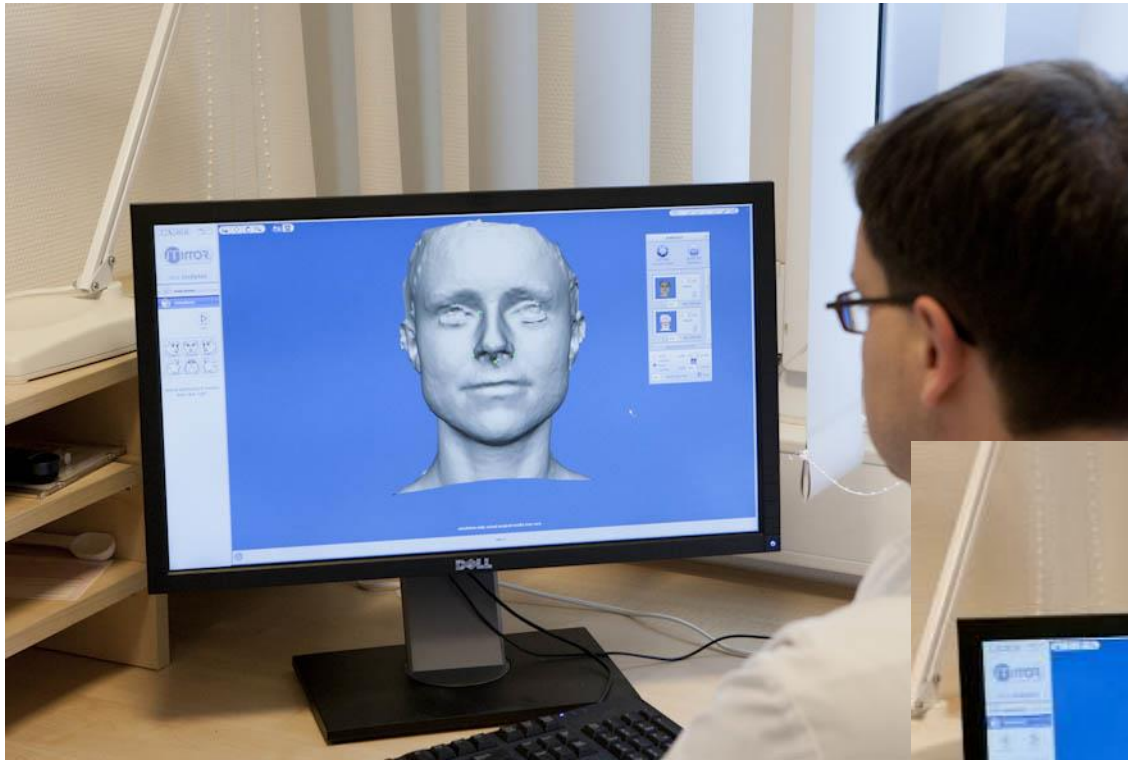- Subjective evaluation by patient and physician
  - Digital photography
  - 3D photography
  - Reflected light microscopy with 30-fold enlargement and polarization
  - Histology on porcine and human explantation
  - Development of a training concept
- 
- Evaluation of the clinic for “hydromassage and lymph drainage “
  - Evaluation of the clinic for hydrocomedolysis and hydroabrasive acne therapy
  - Evaluation of the penetration depth of the fractional hydroporation of liquid, viscous and crystalline substances.



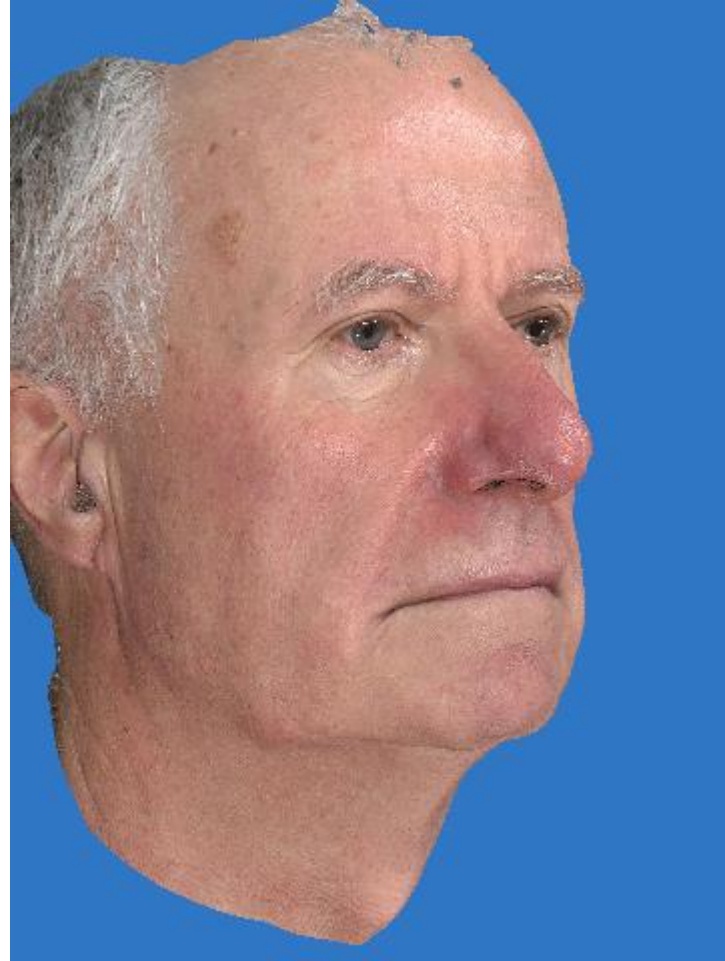

# 3D Photographes



# 3D Photographie



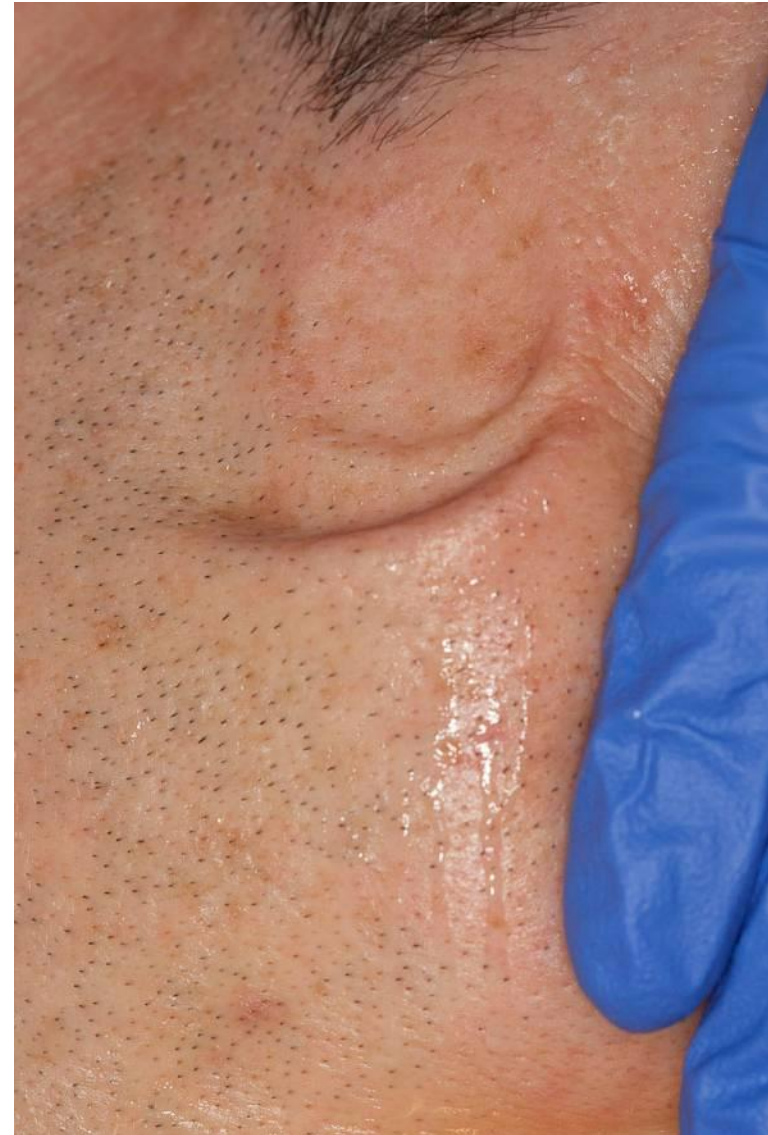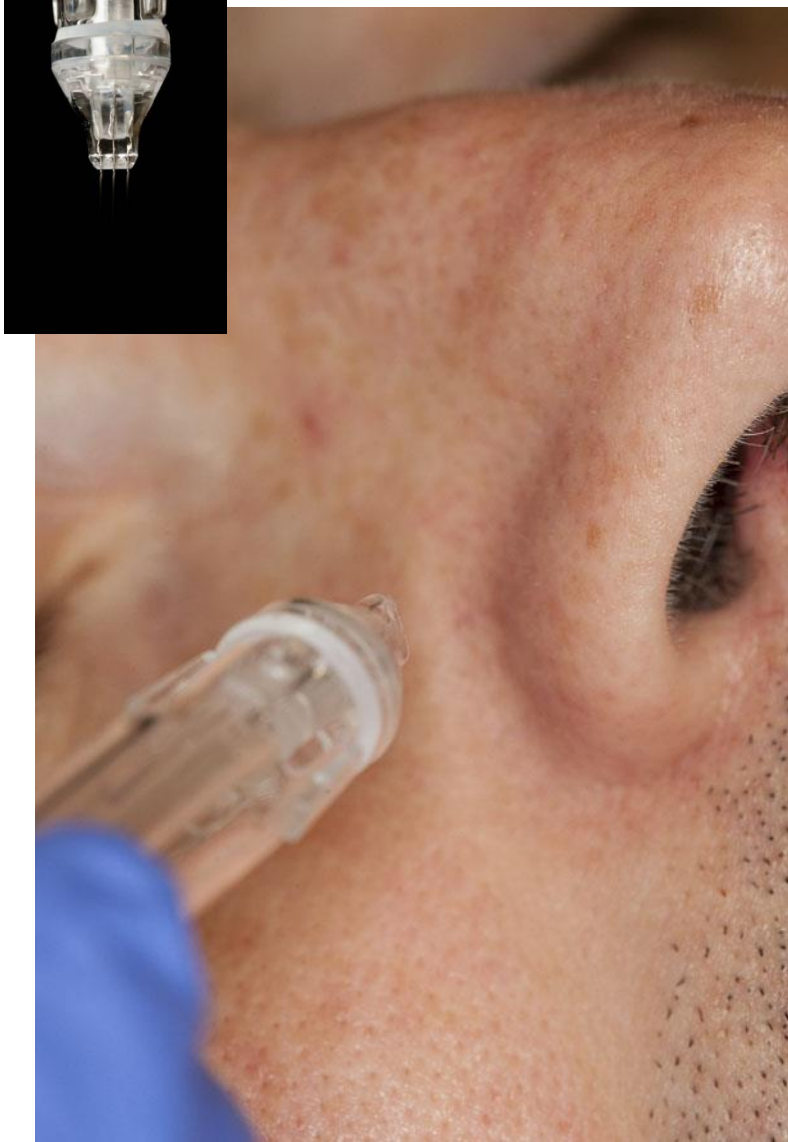# Evaluation



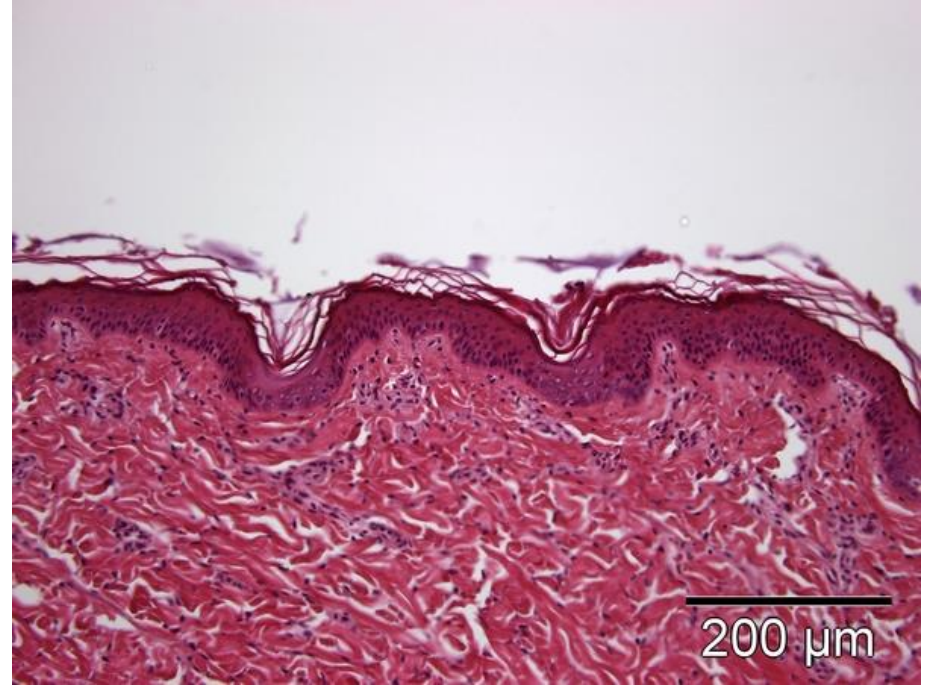
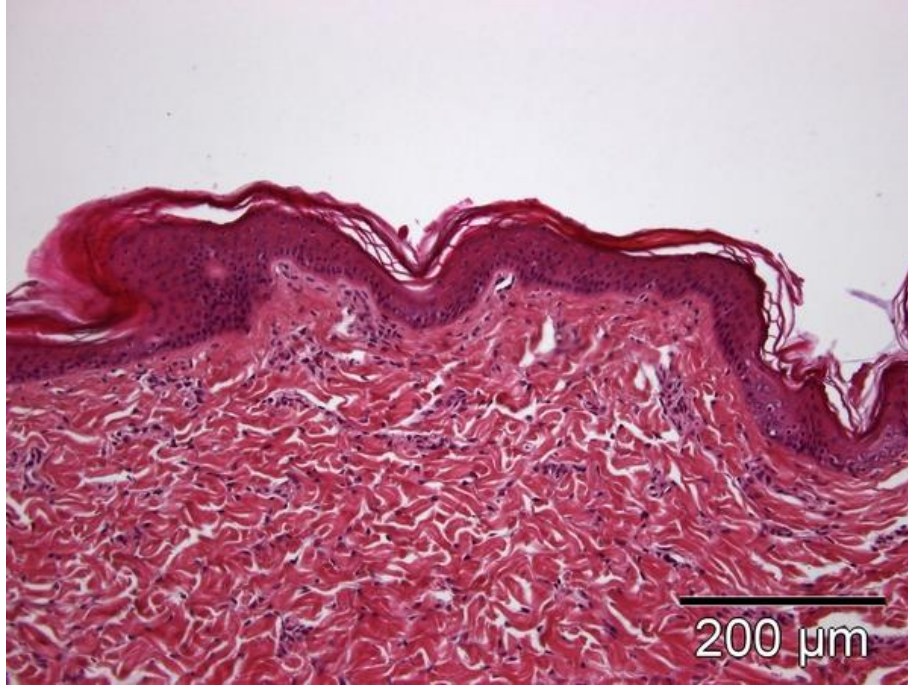
# Evaluation



# Clinic for Hydroporation – “Massage / Lymph drainage“

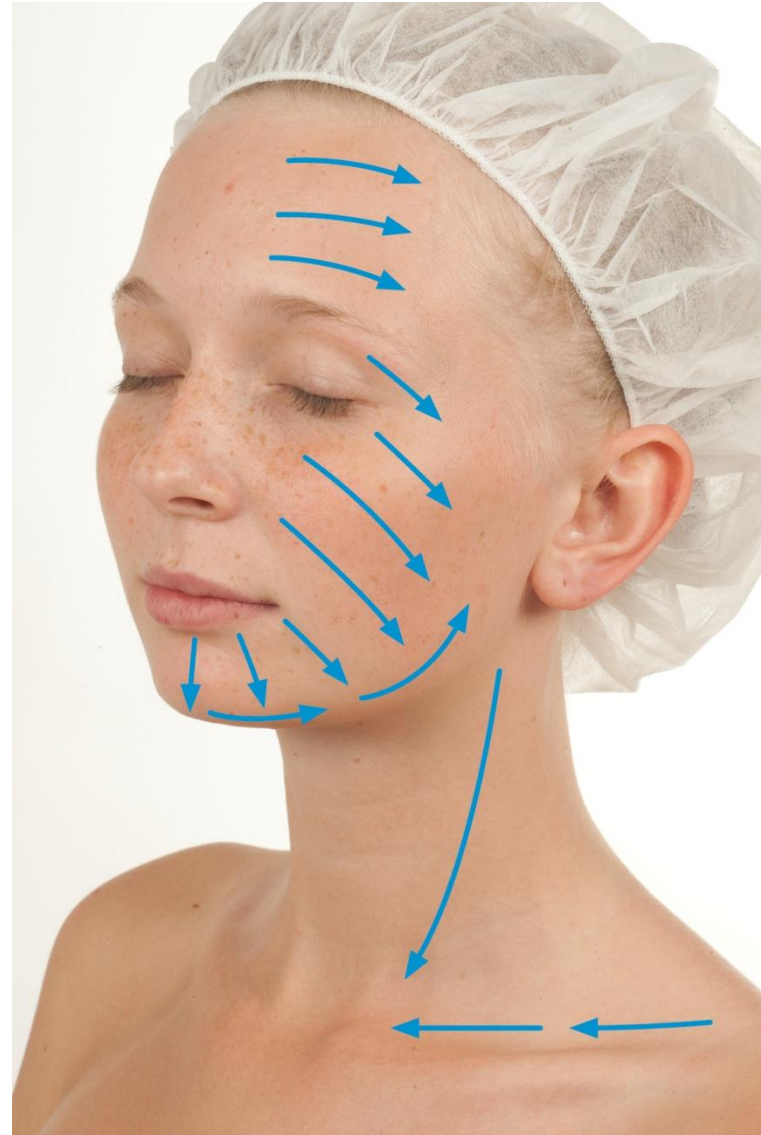

# Massage Histology

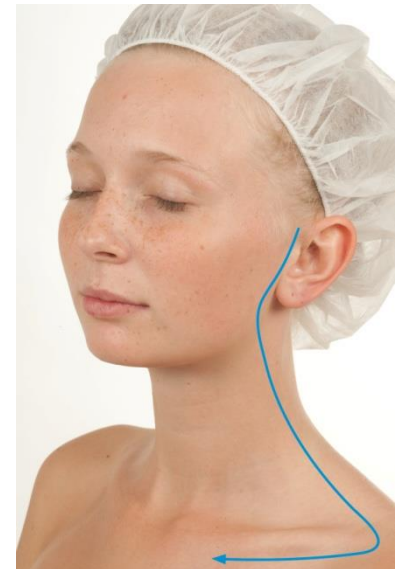
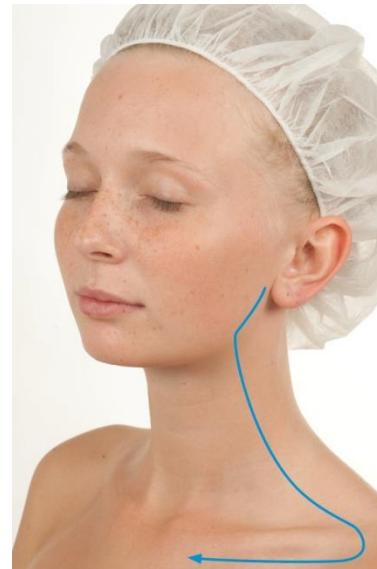
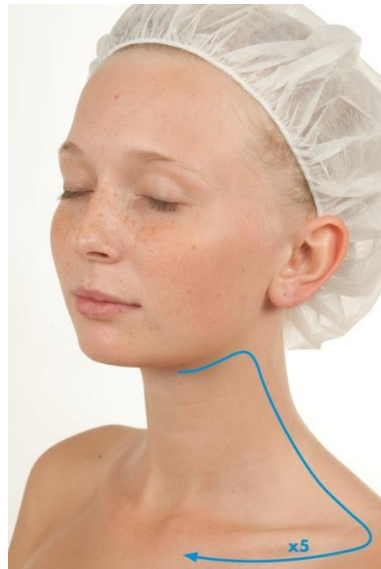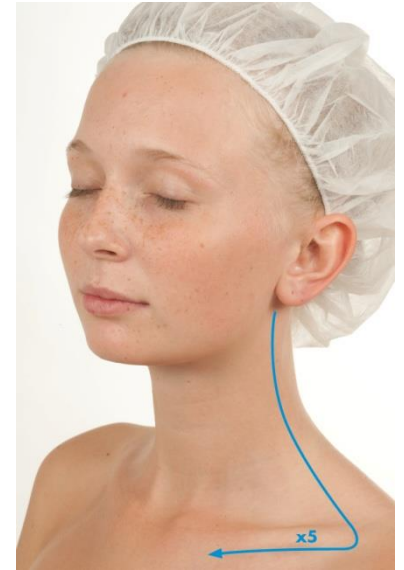Intact epidermis  
Conservation of Str. corneum

# Lymph drainage technique

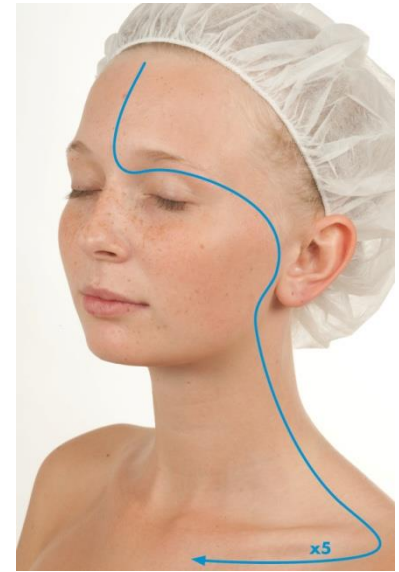
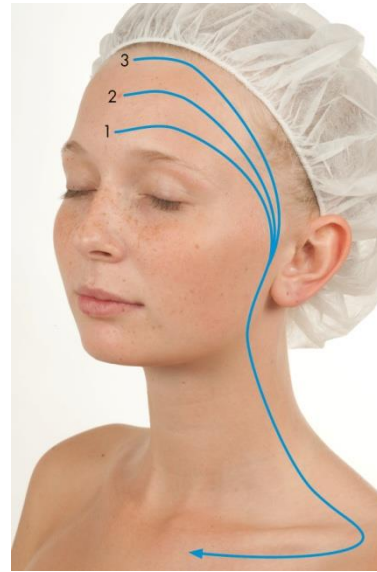
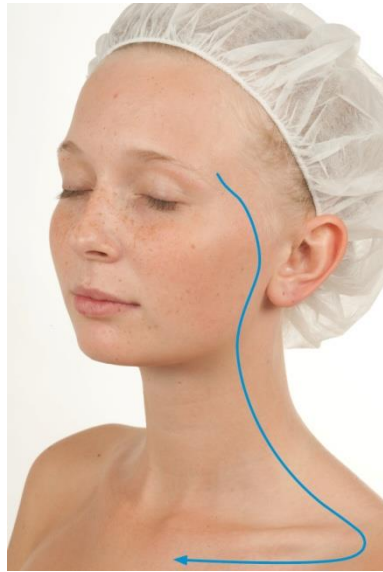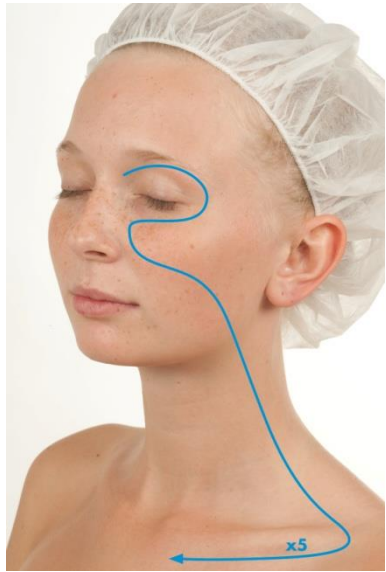# Lymph drainage technique





# Lymph drainage technique



5-10 cm distance from the skin

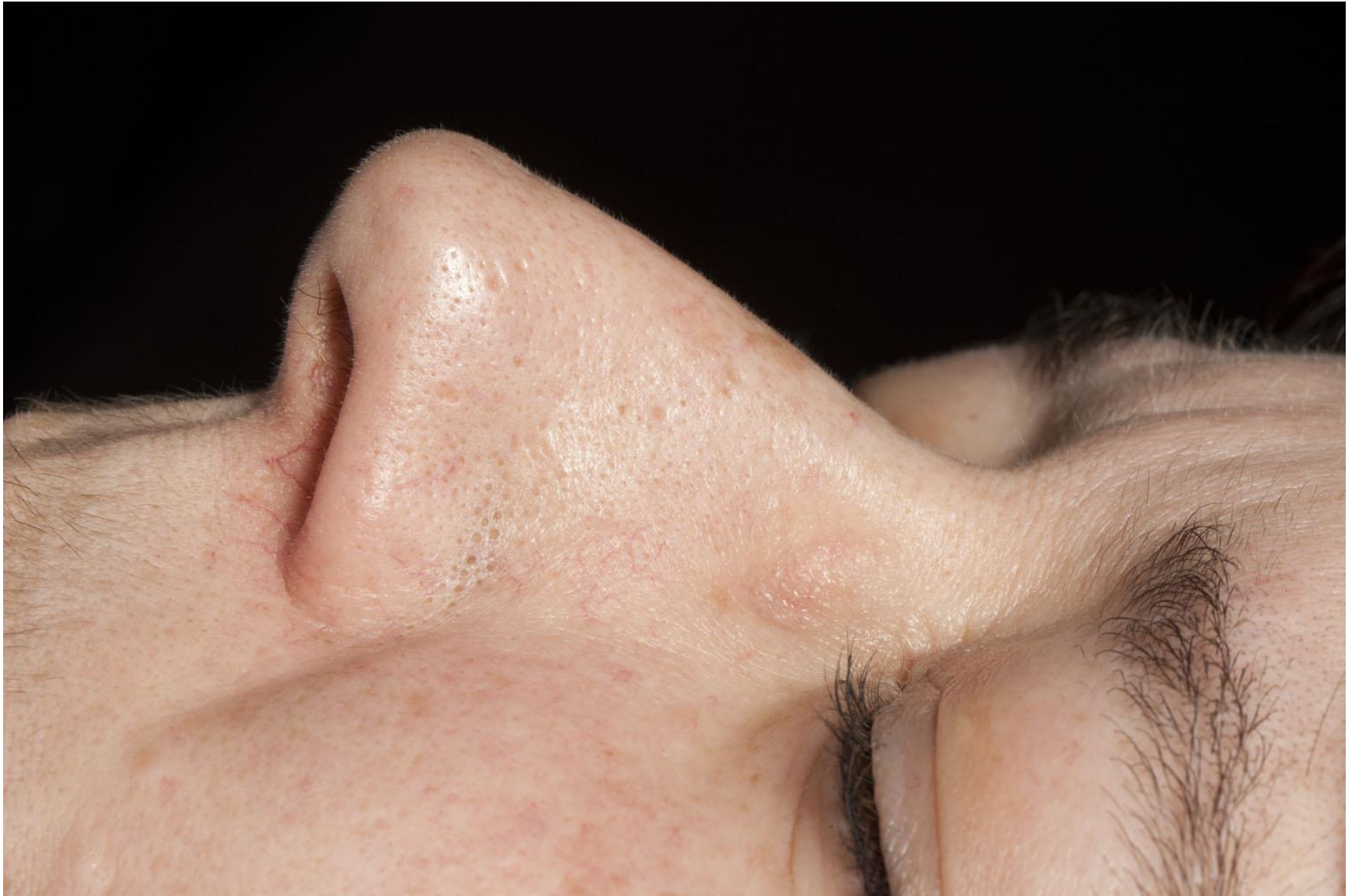90° to the skin surface

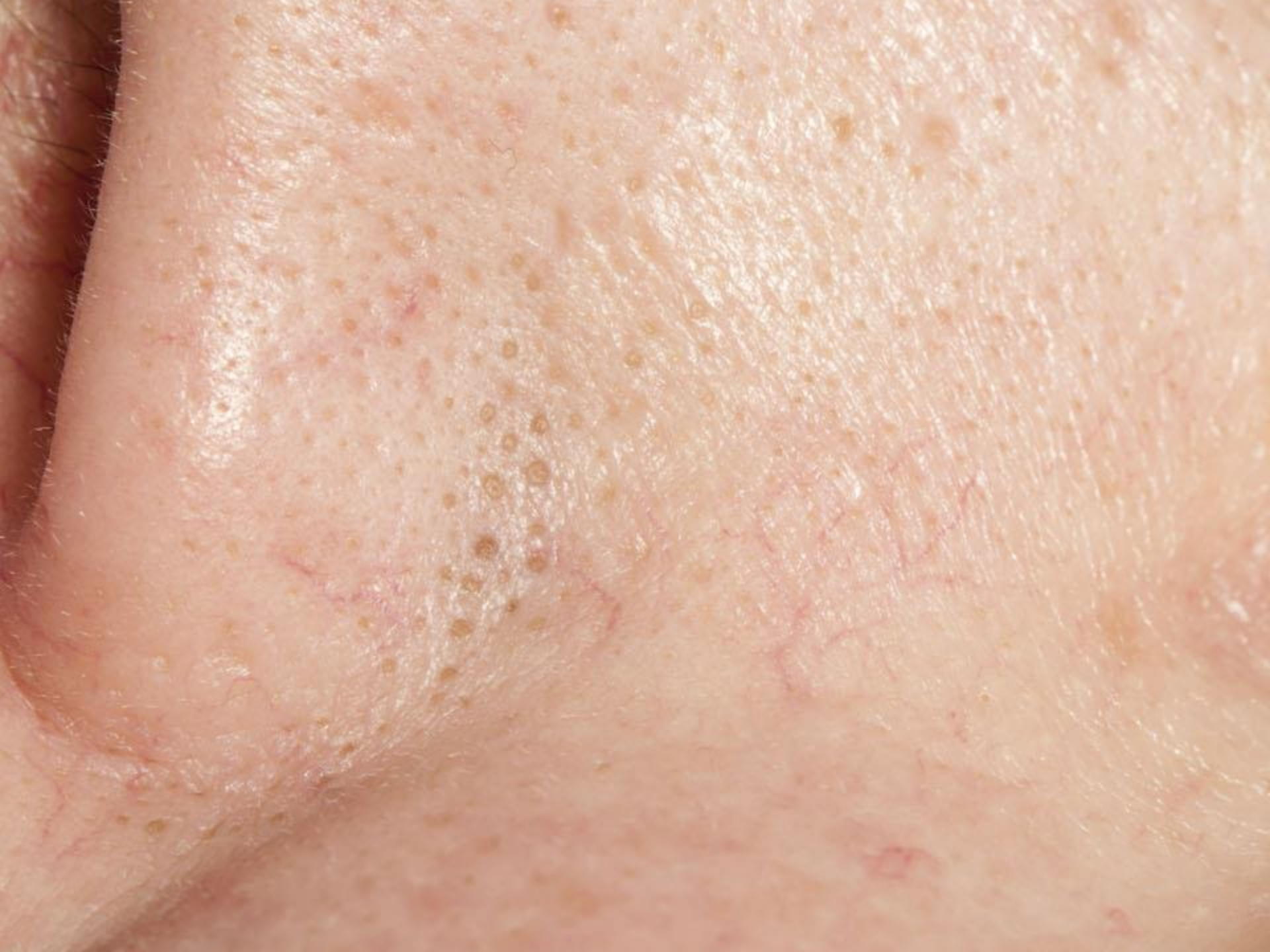Continuous movement

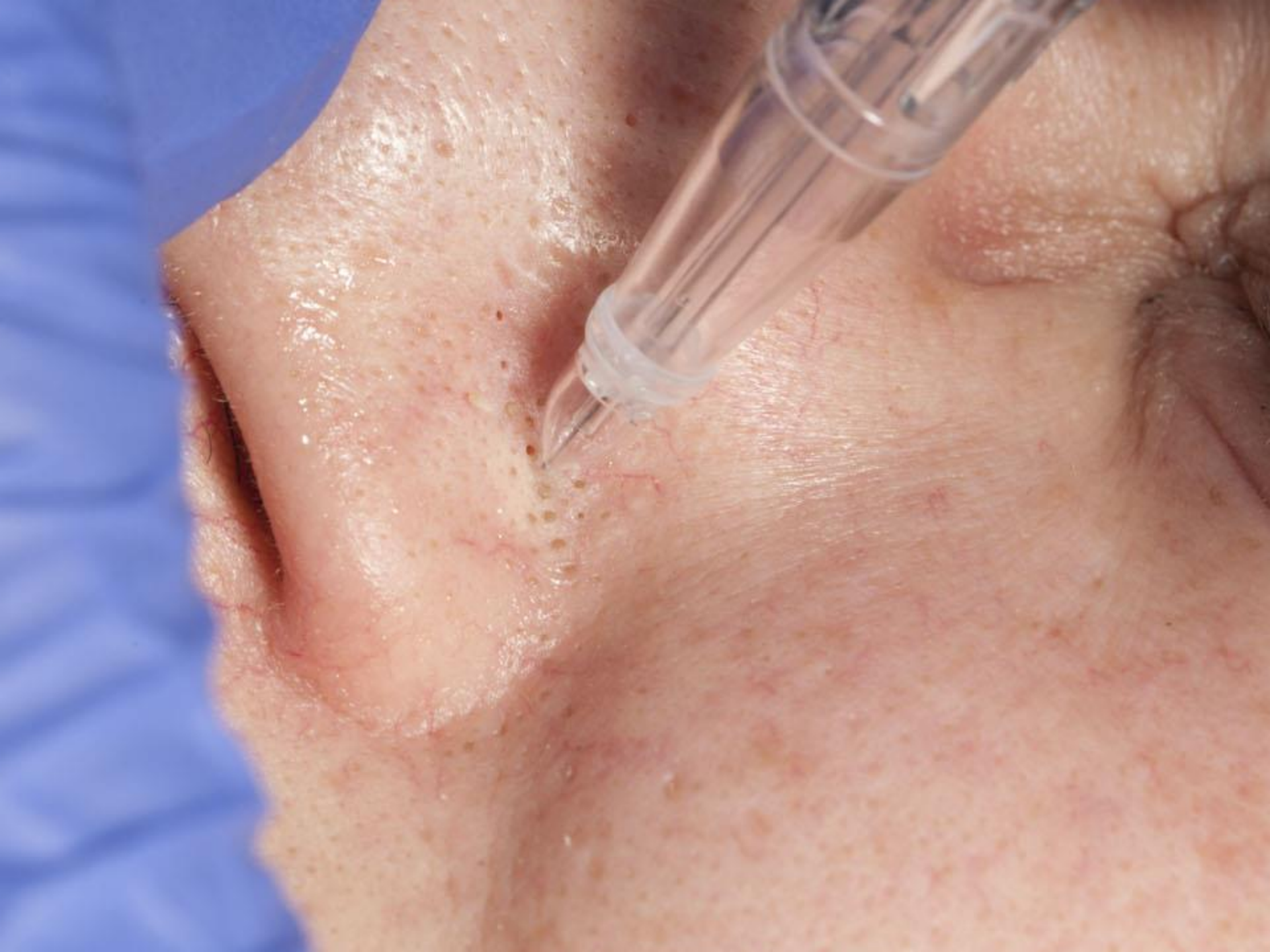Protect of the orifices of the eyes, the nose and the ears, eye lids and lips

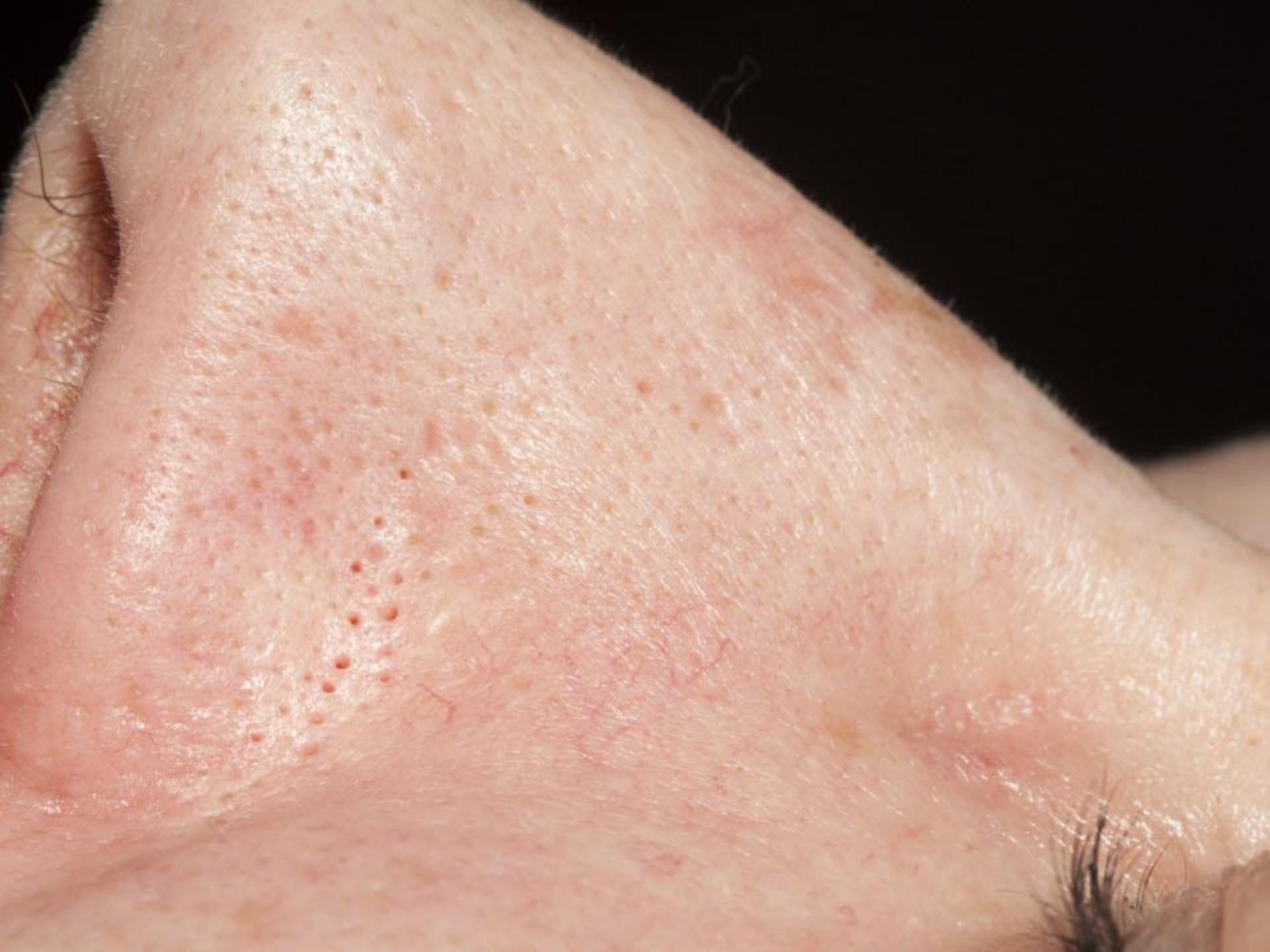First the left half of the face, then the right half

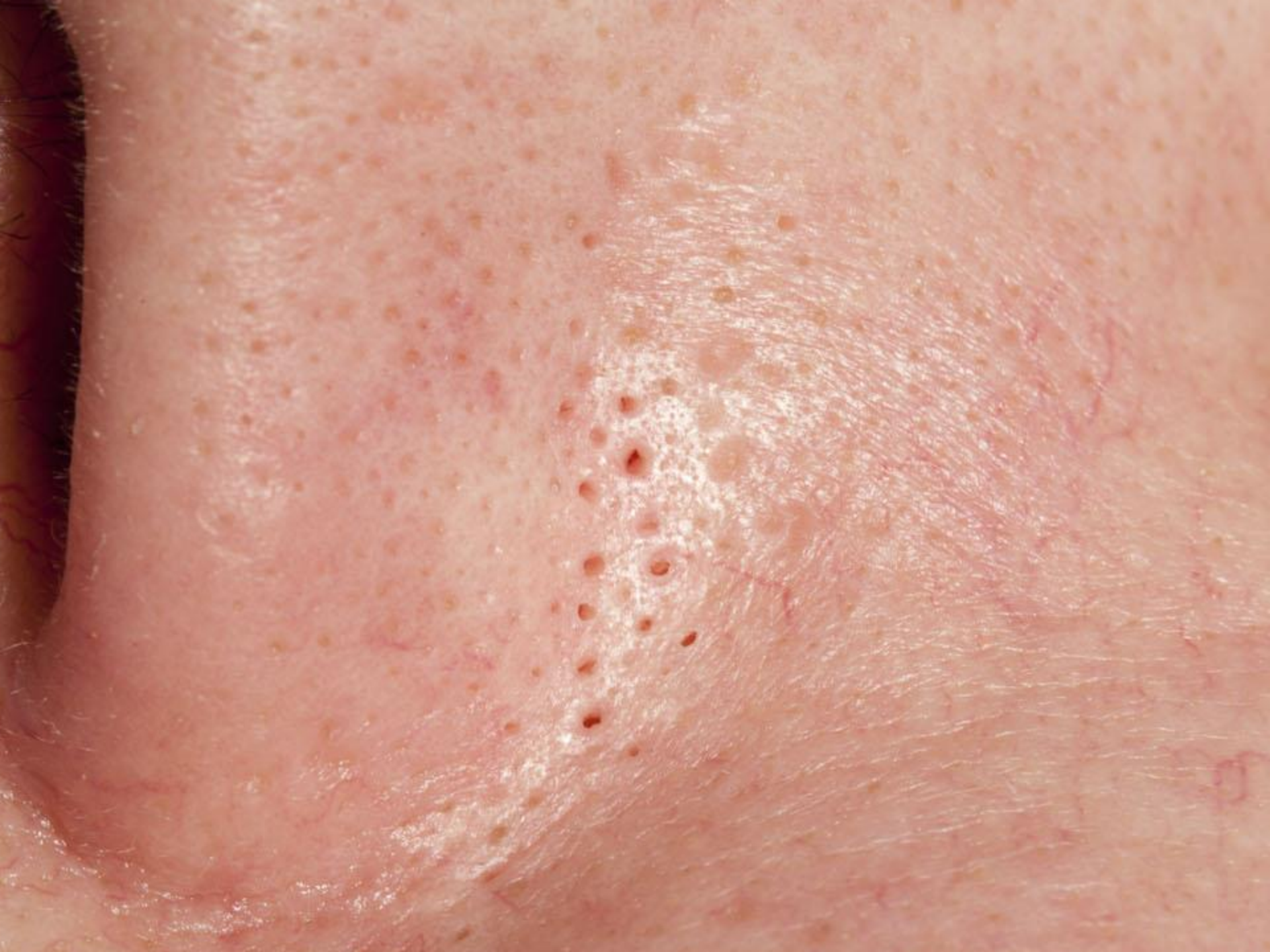# Evaluation of hydrocomedolysis and hydroabrasive acne therapy

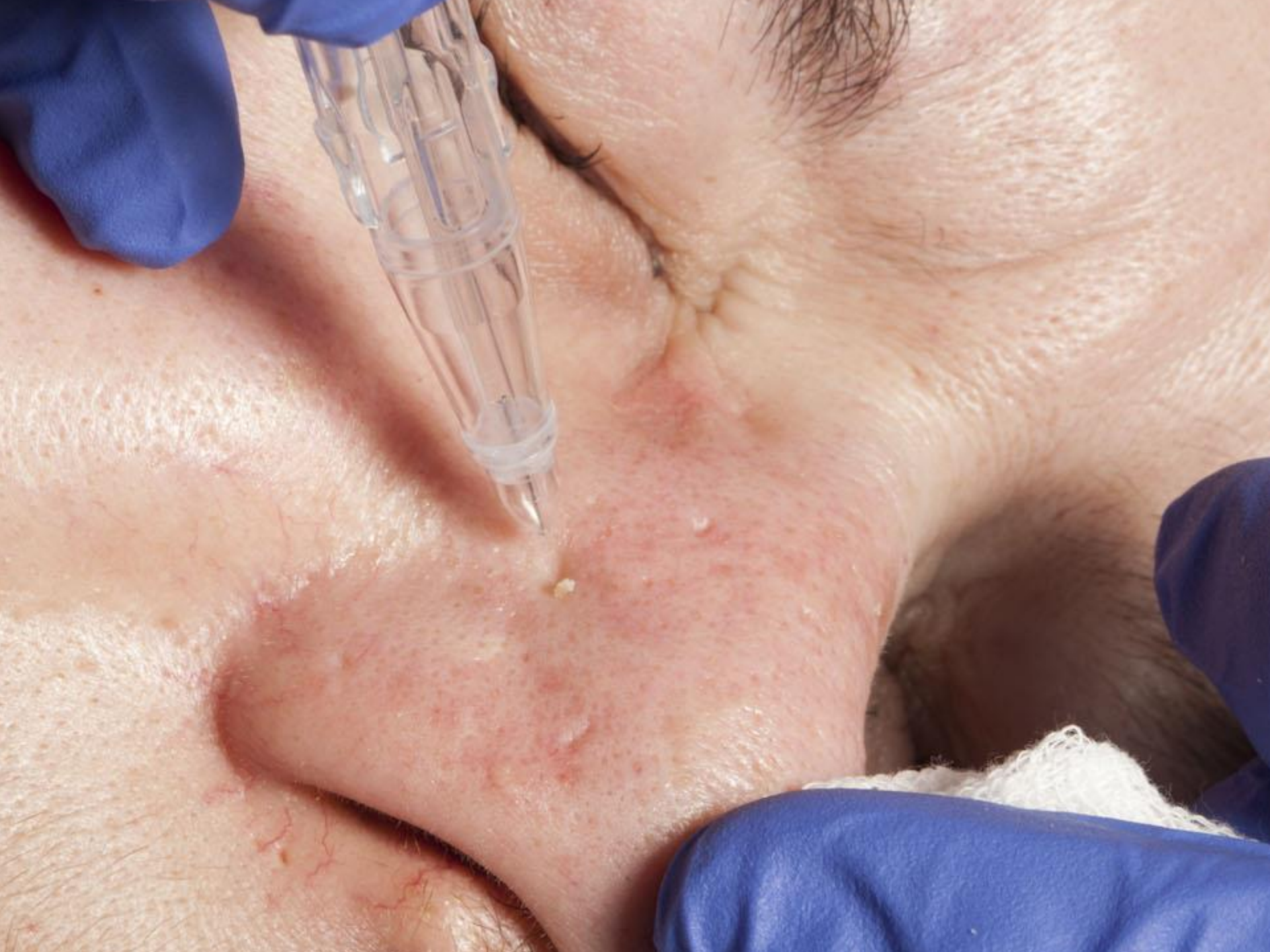




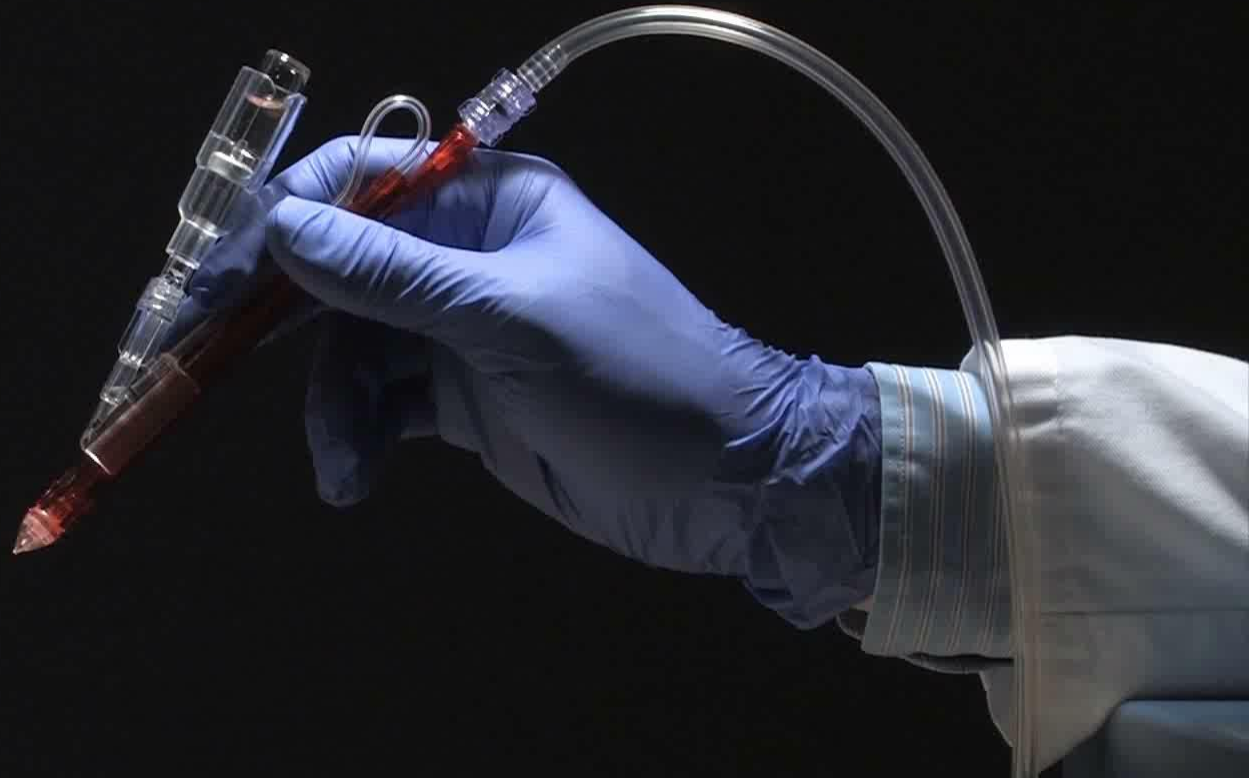






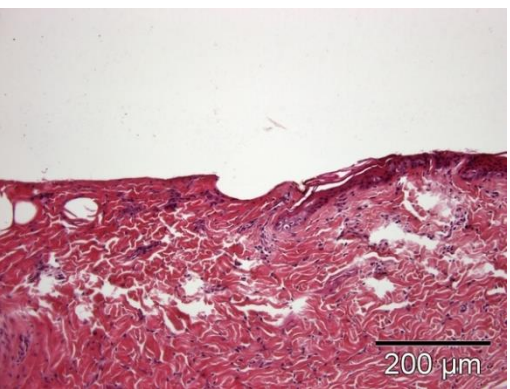
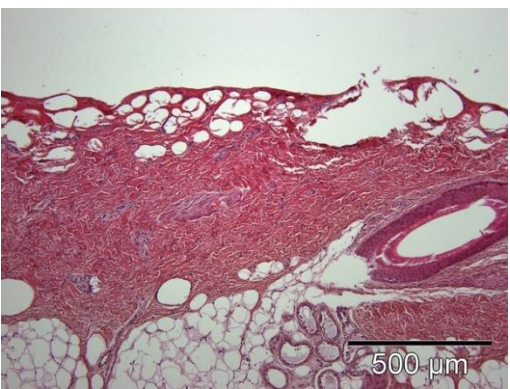
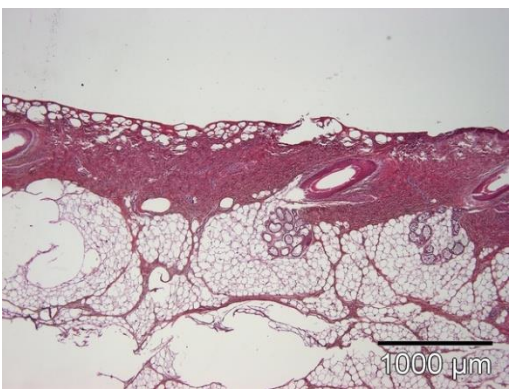
# Procedure




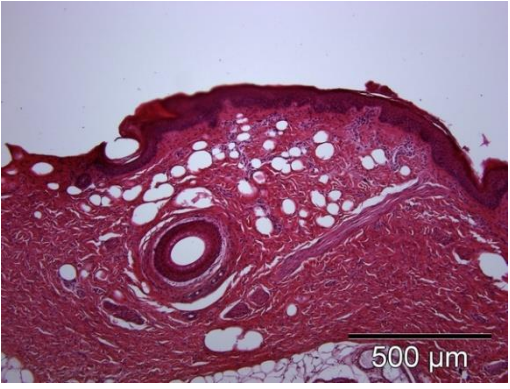
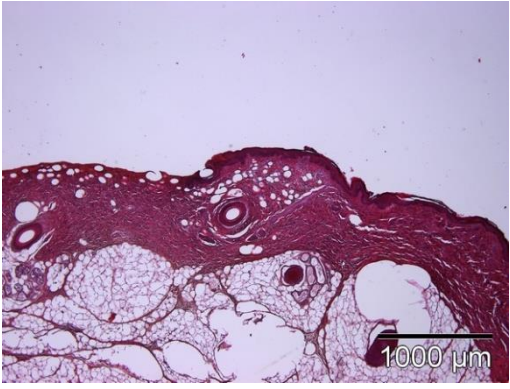


# Hydro-abrasion and injection from 1cm distance to skin

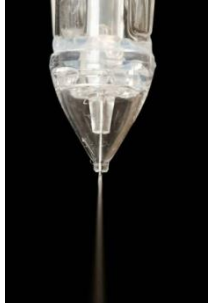1 min



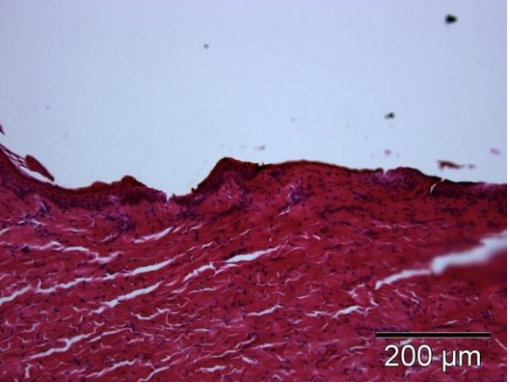
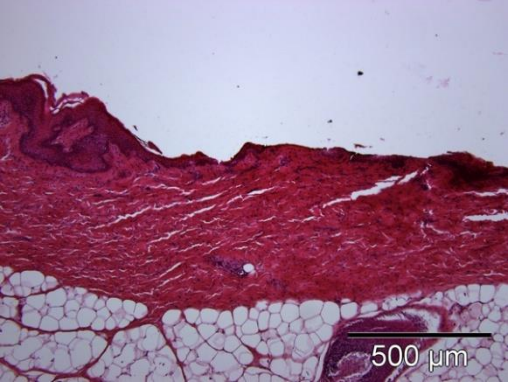
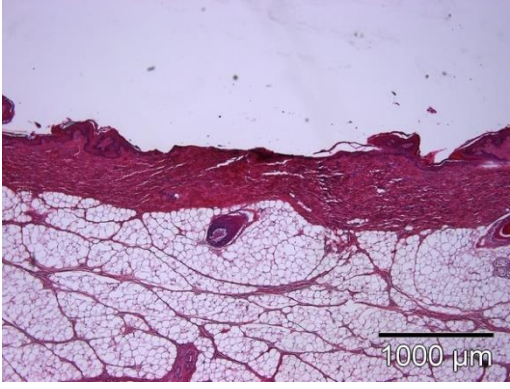
30 s



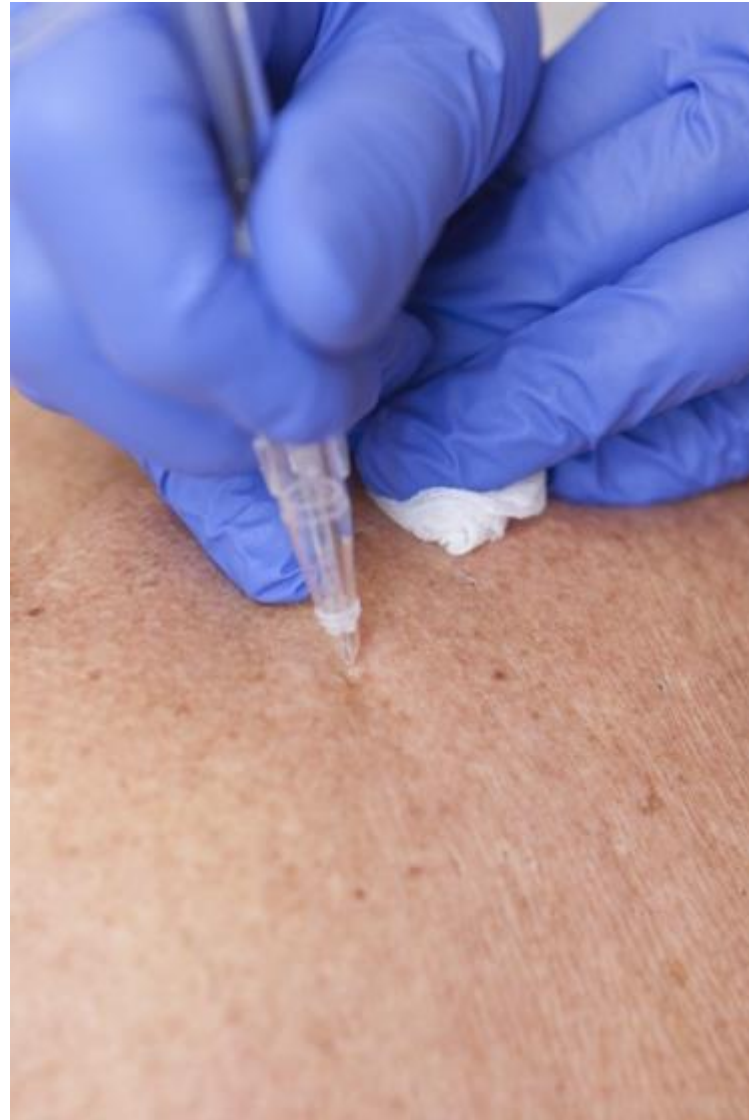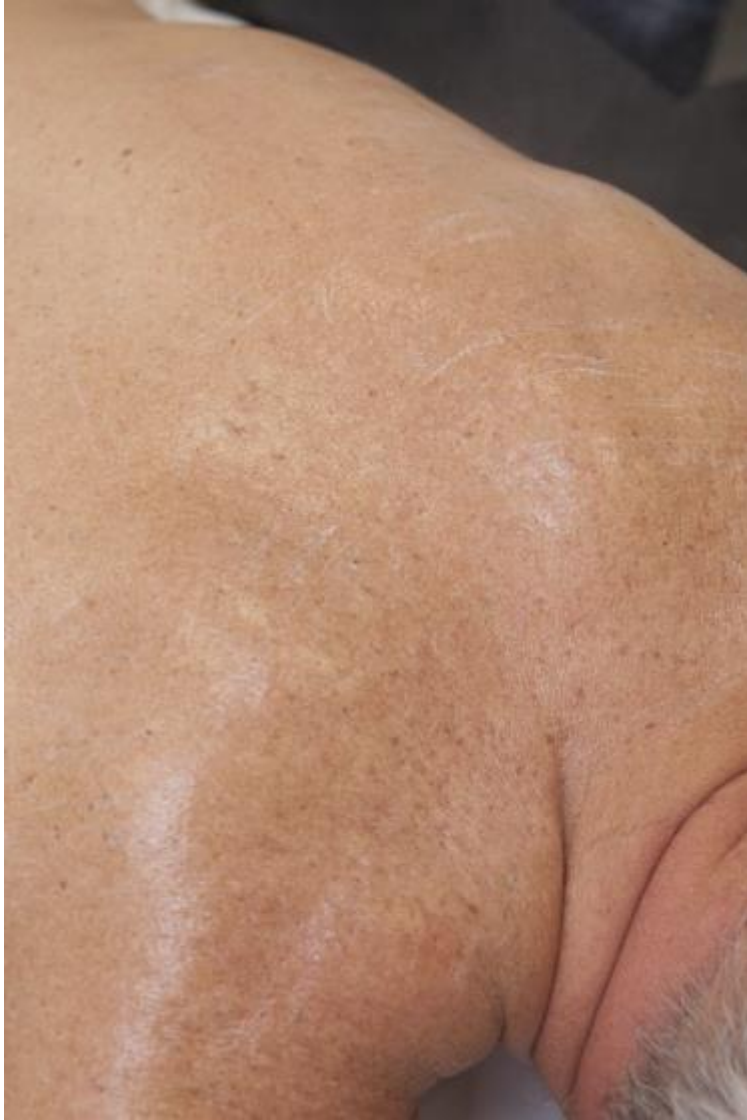0,5-1 cm Abstand  
45-90°



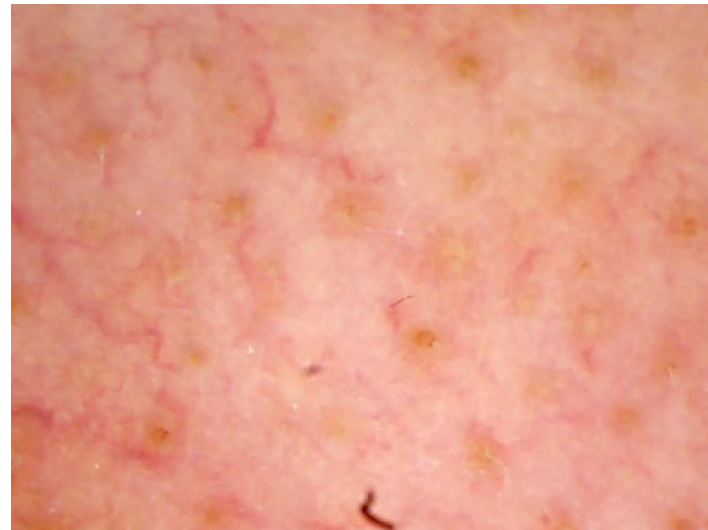
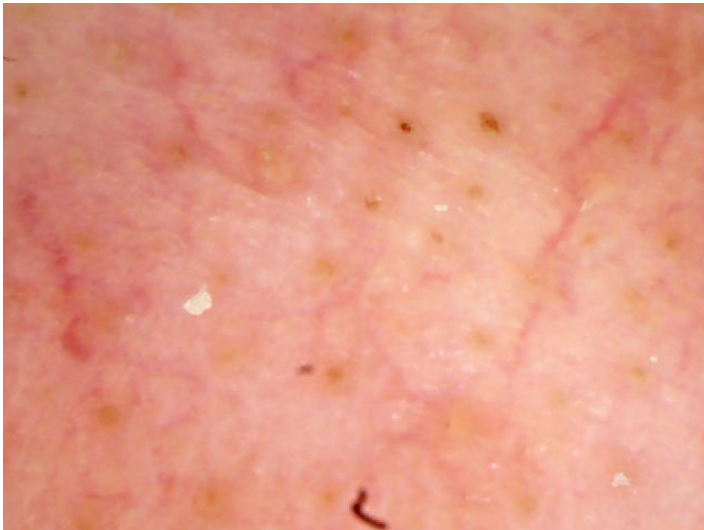
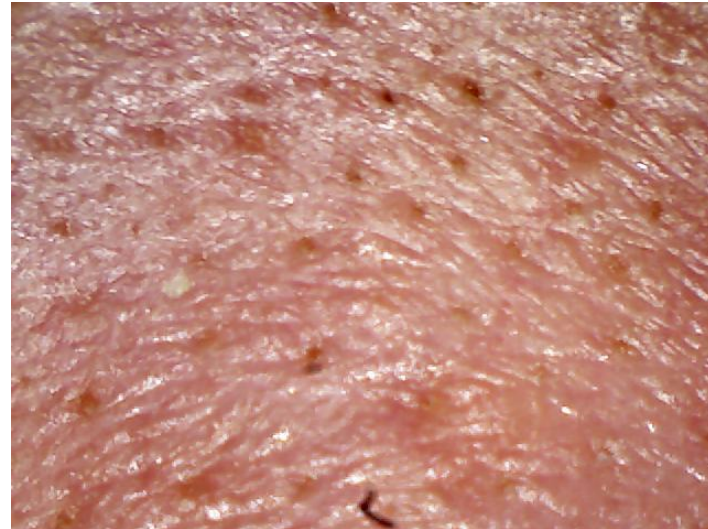
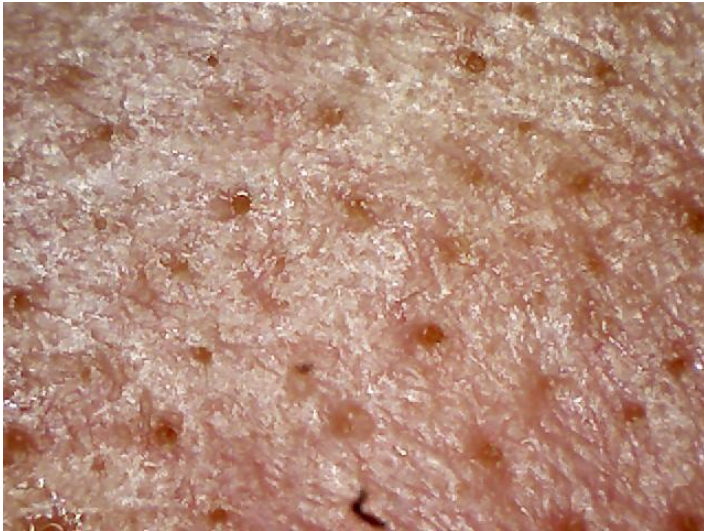
10 s



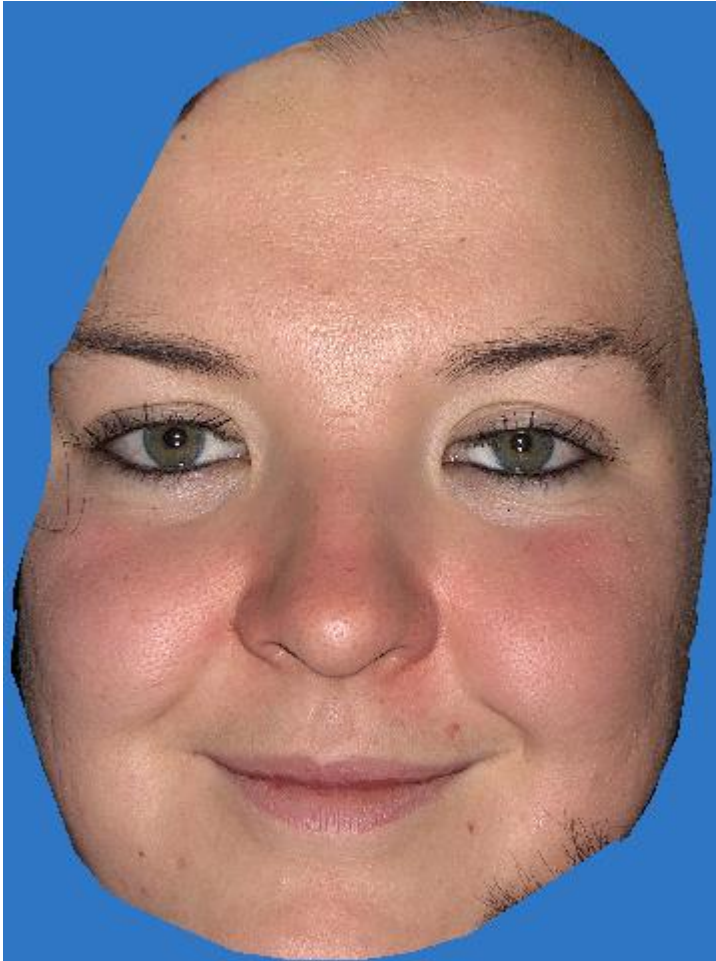
# Clinic for reflected light microscopy



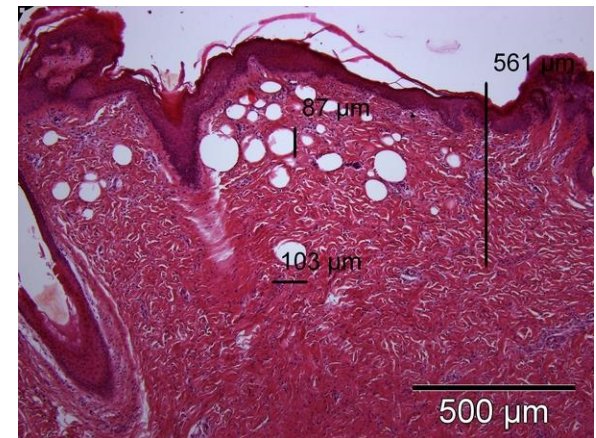
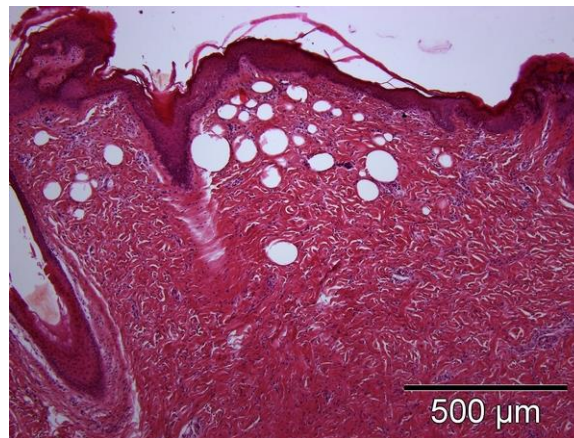
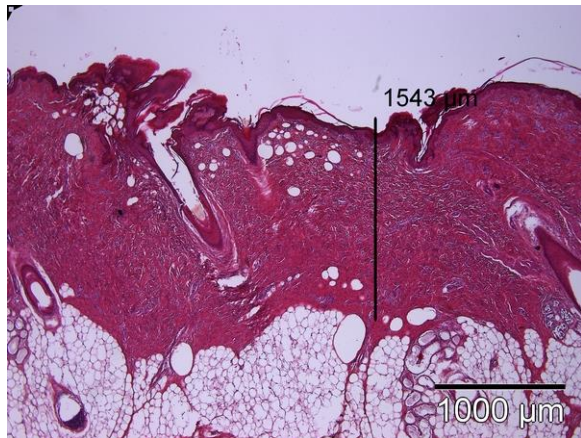
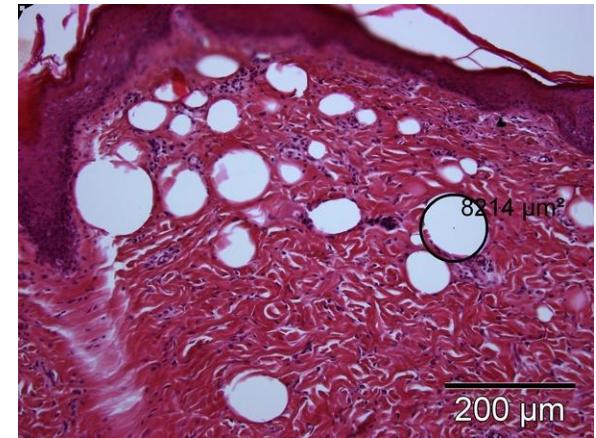
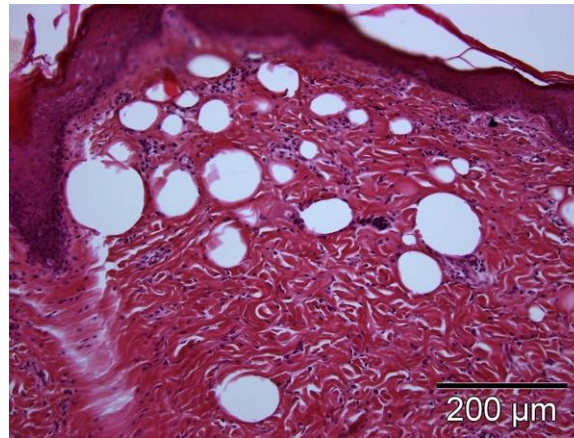
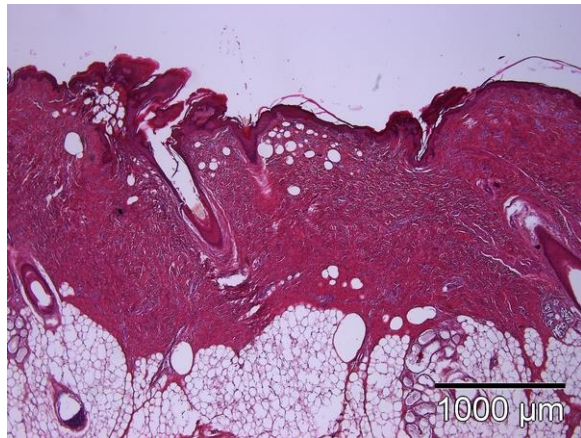
# Clinic for reflected light microscopy



# Clinic 3D Photographs

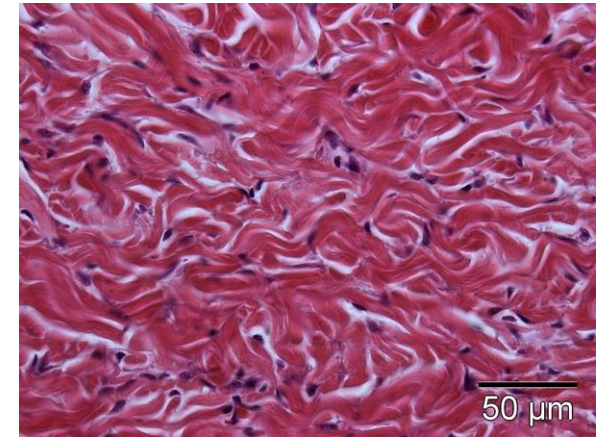
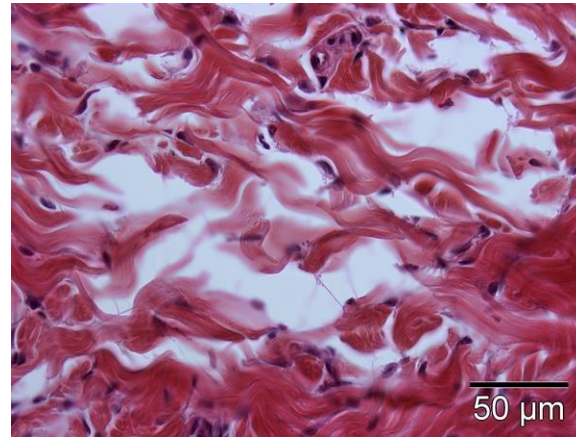
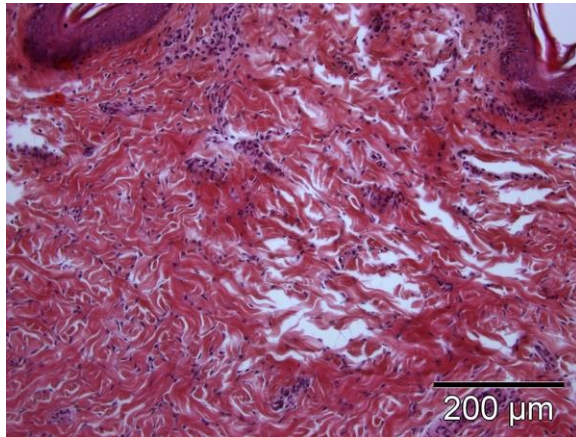
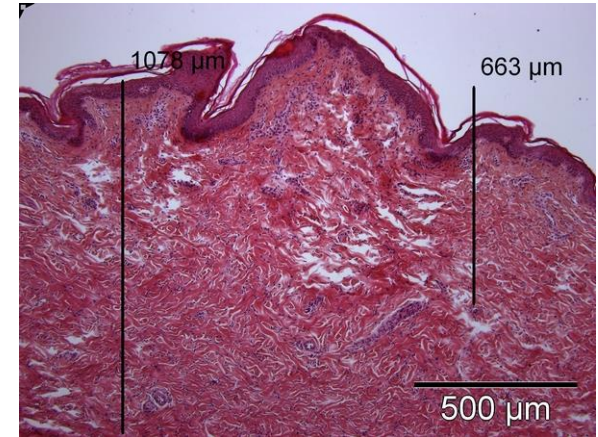
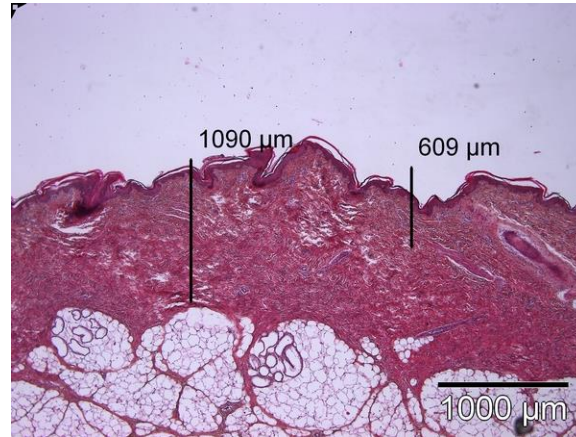
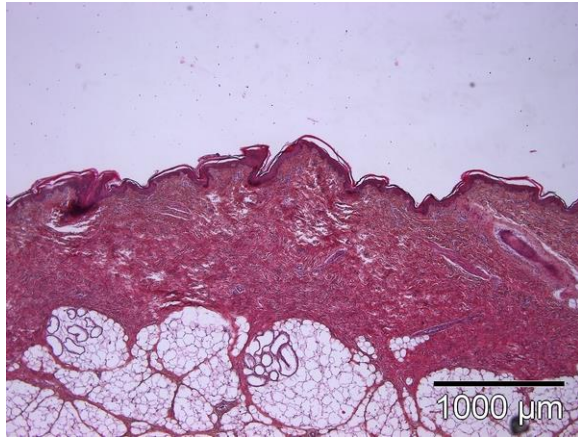


# Hydroporation Histology H2O Inject 30s



Creation of dermal interstitial spaces in intact epidermis

# Vitamin A inject 10s

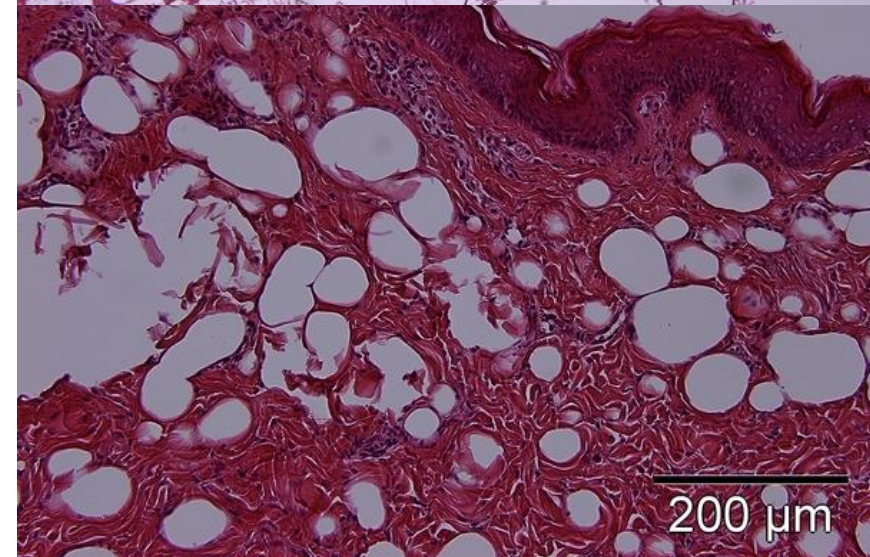
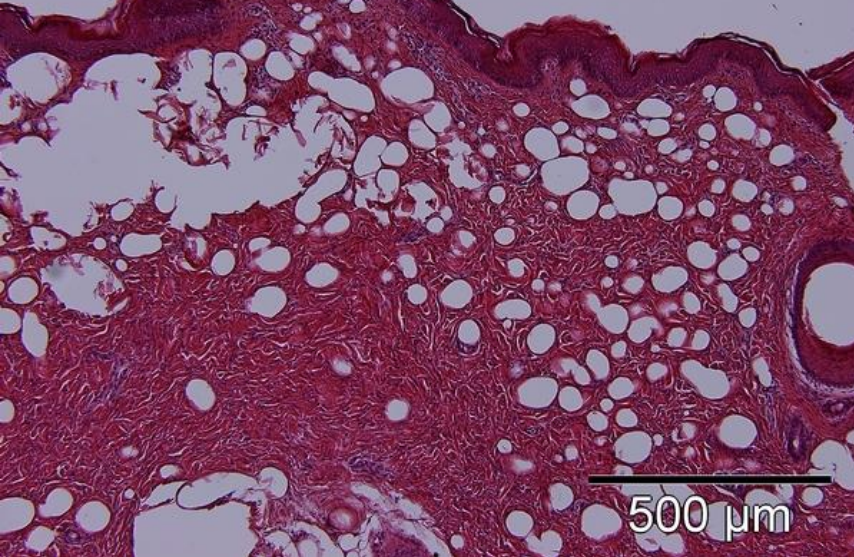
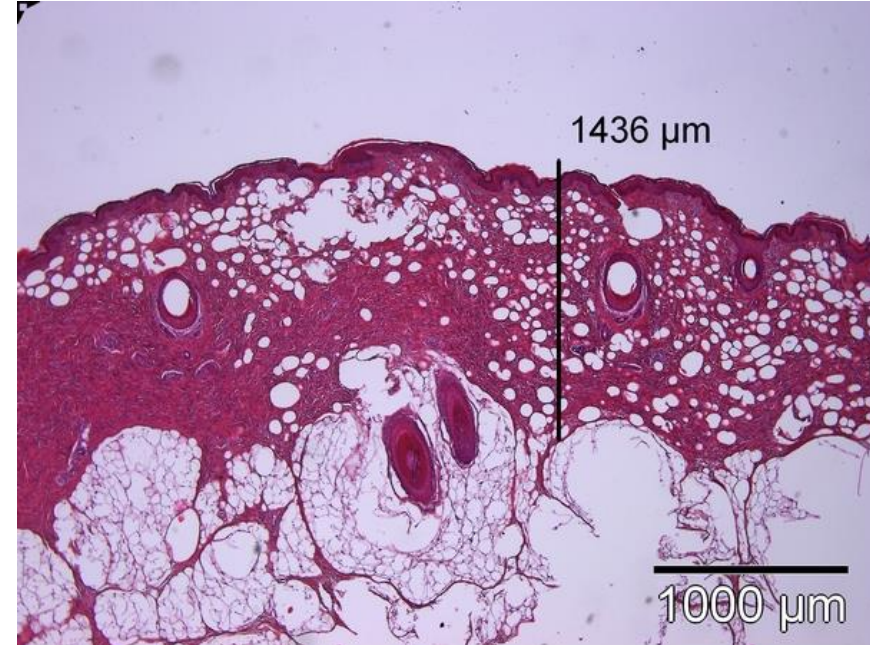
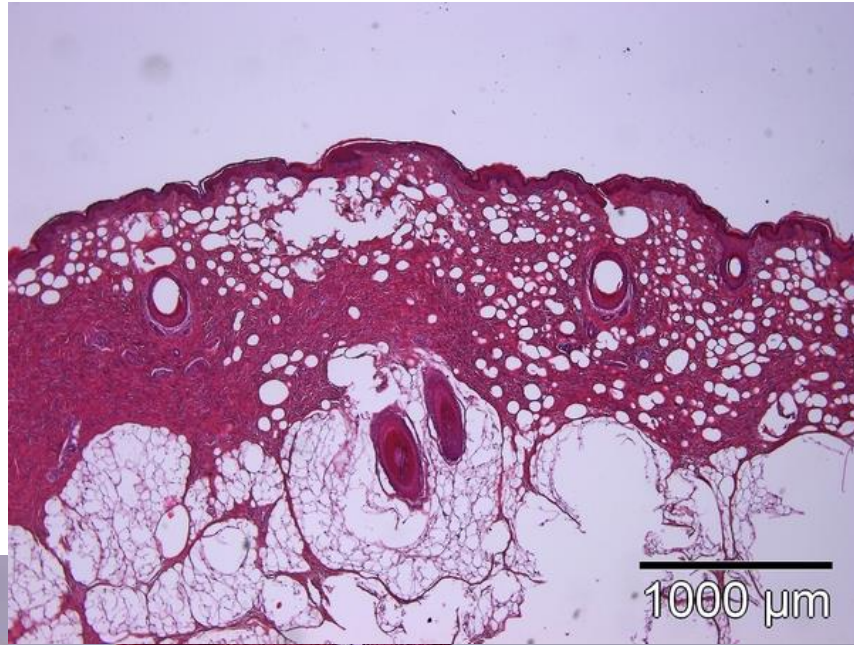

Kontrolle

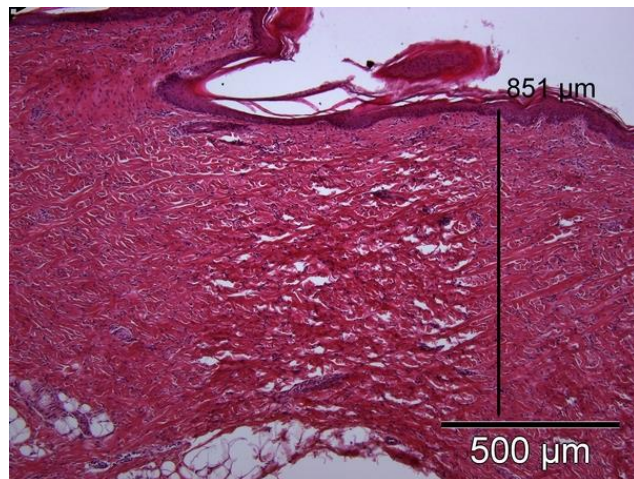
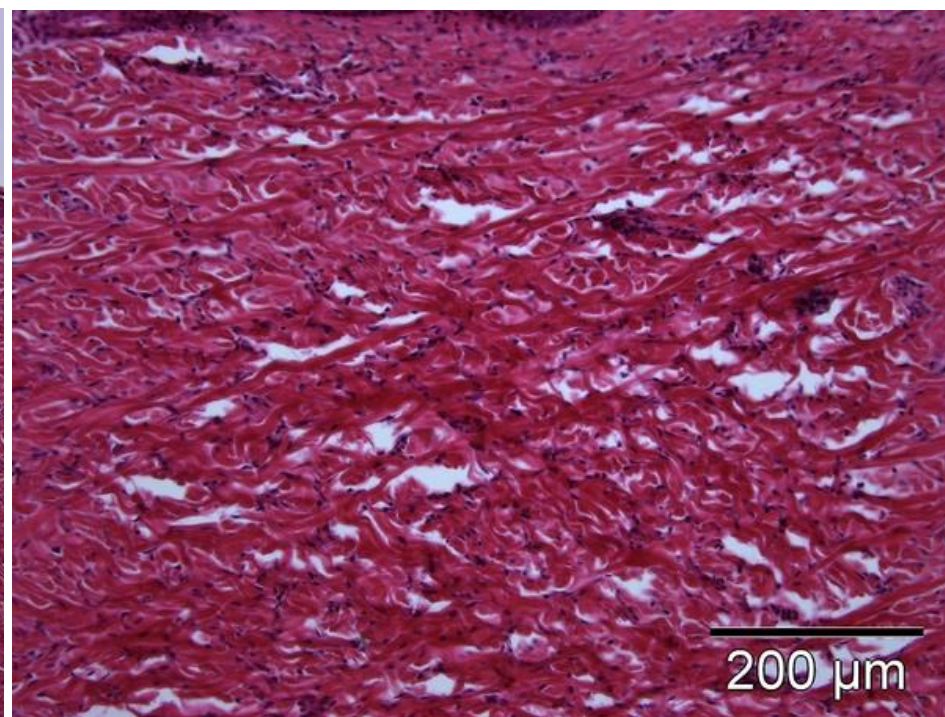
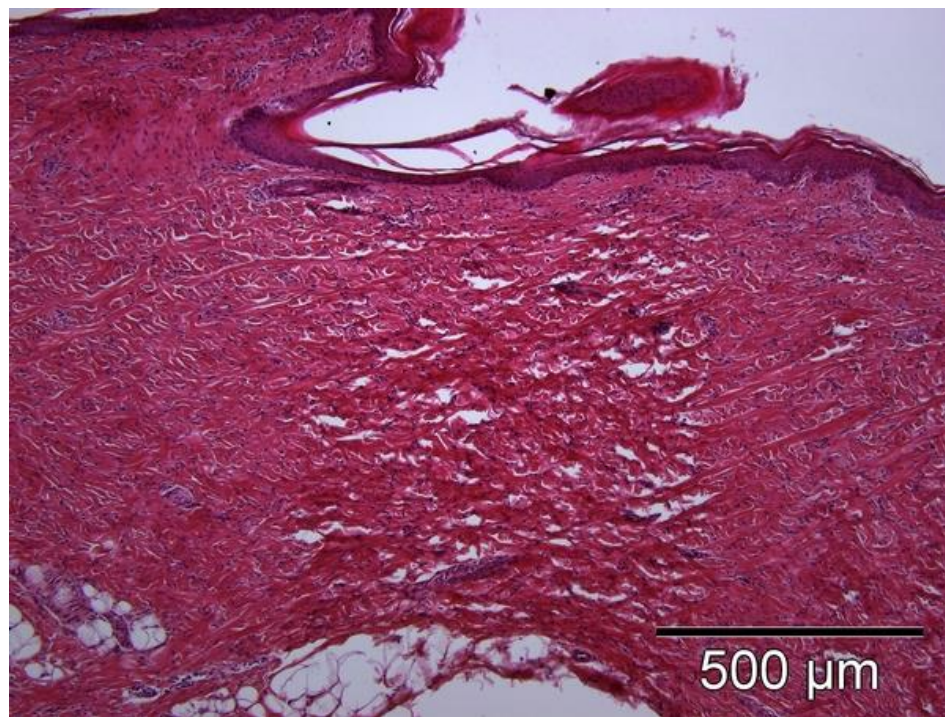
The targeted application Vitamin A on an area of a few square centimeters over 10s results in

- Focal horizontal abrasion of the epidermis
- Insertion of small to medium volumes between fibers with "feathering" as compared to control
- Section-wise in-depth application of large volumes

# Hydroporation Vitamin A inject 30s



# Vitamin C inject 30s

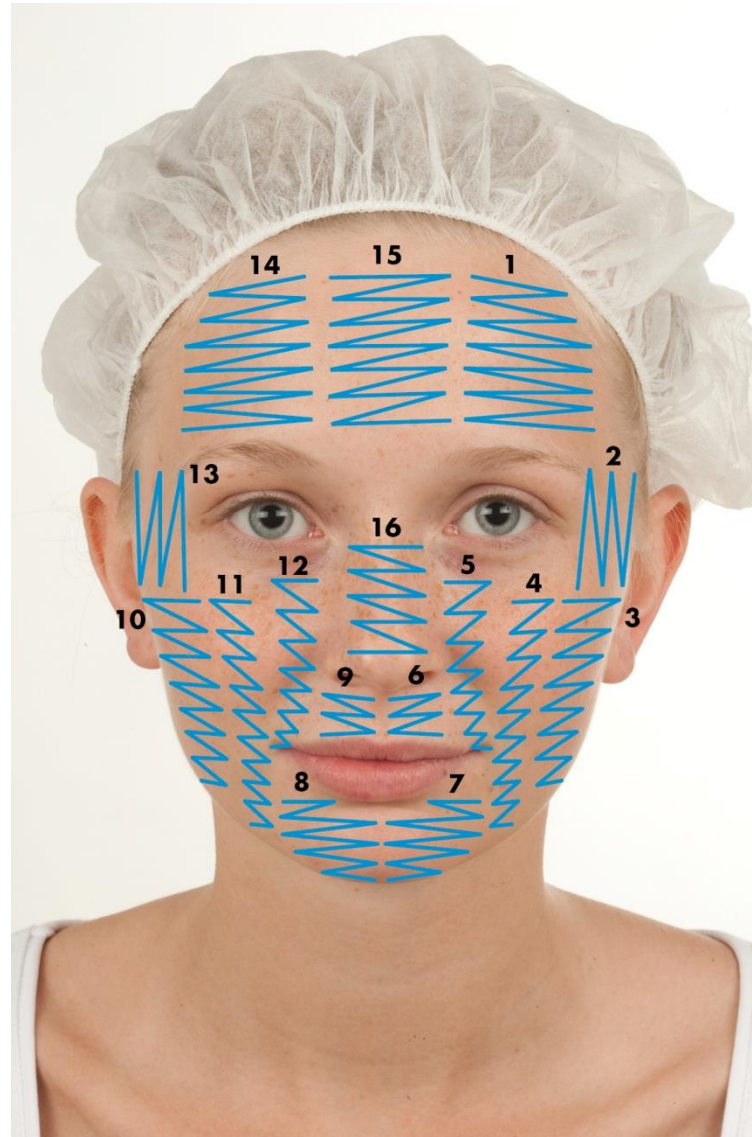


The targeted application of vitamin C on a surface area of a few cm<sup>2</sup> over 30s leads to liver

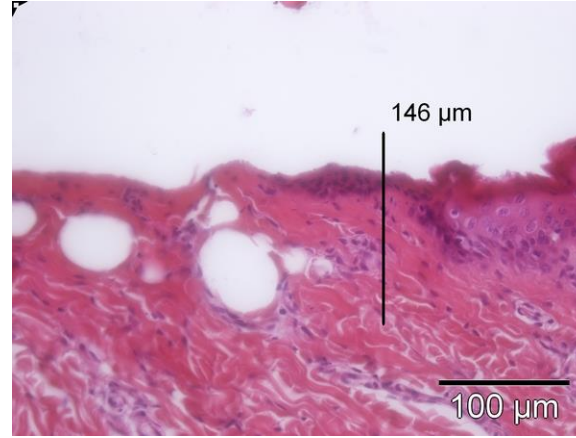
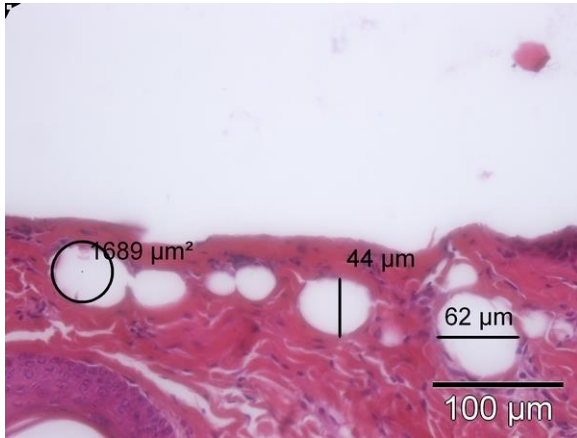
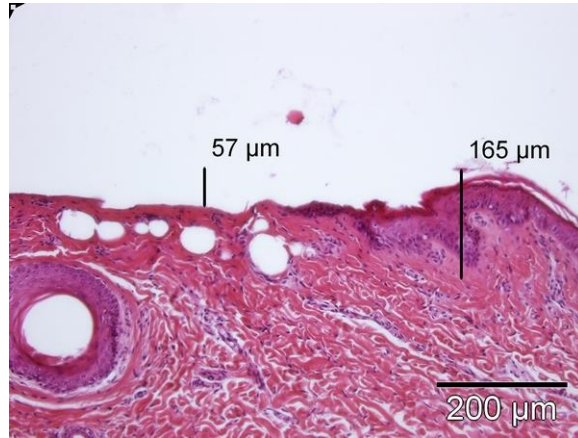
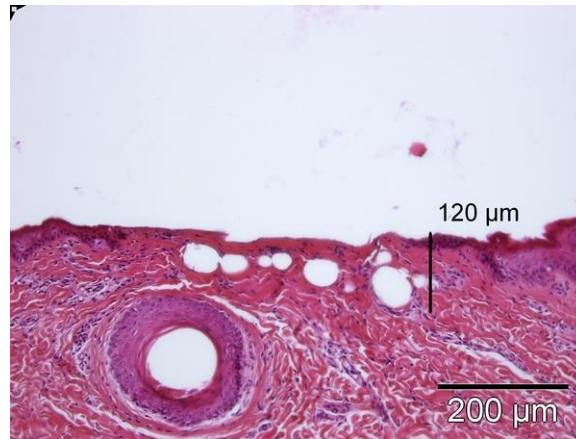
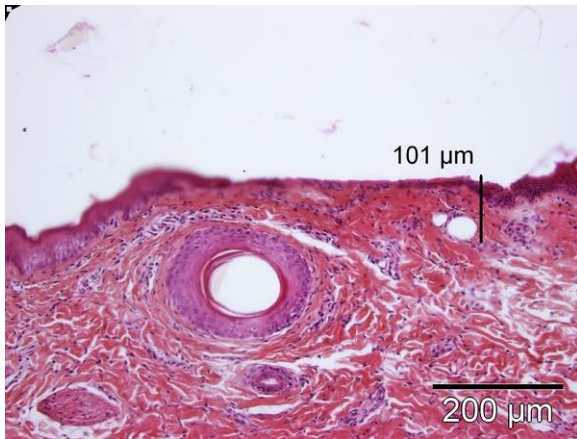
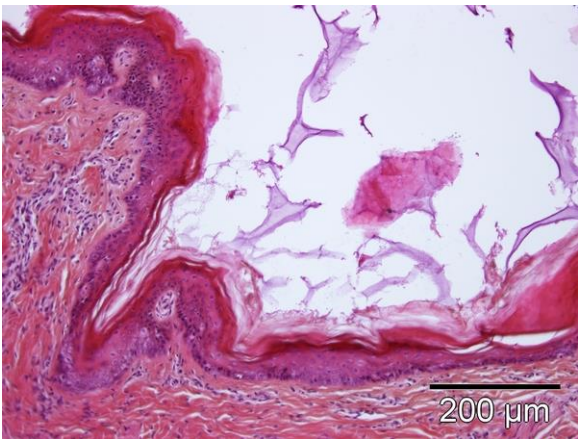
- Focal horizontal ablation of the epidermis
- Transfer small to medium volumes between the fiber with "Aeroelastic deformazione"



# Hydroabrasion and injection technique



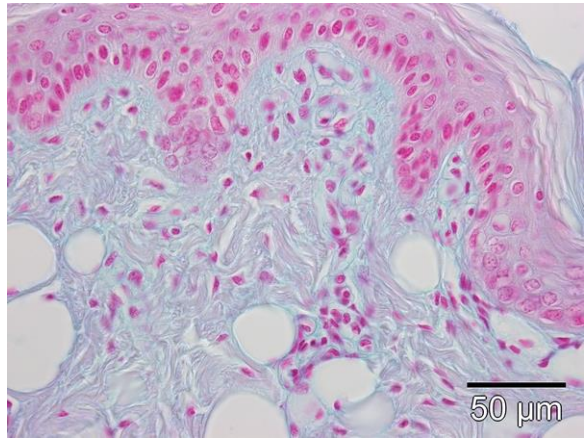
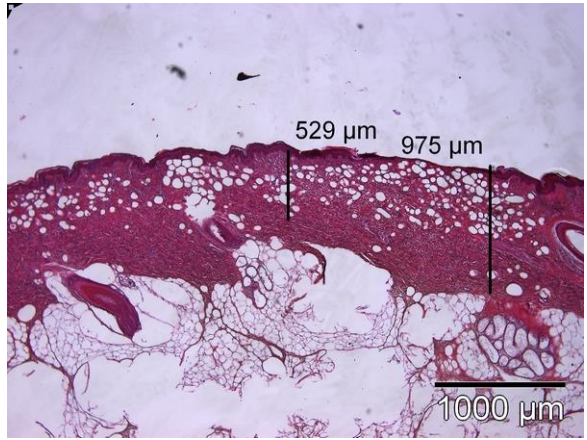
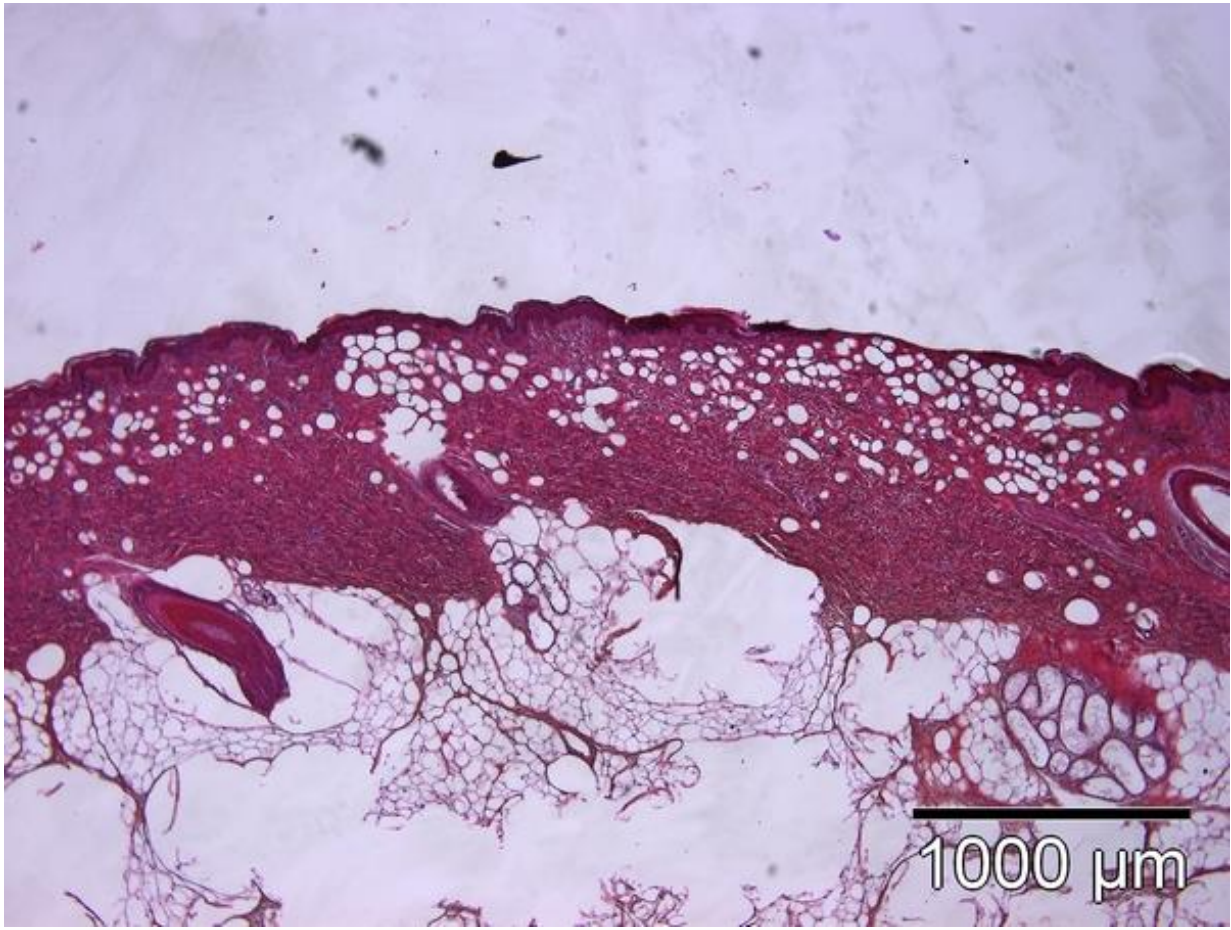
# Pneumoporation of low-viscosity substances



The targeted application of non-networked hyaluronic acid to a surface of a few cm<sup>2</sup> over 30s leads to

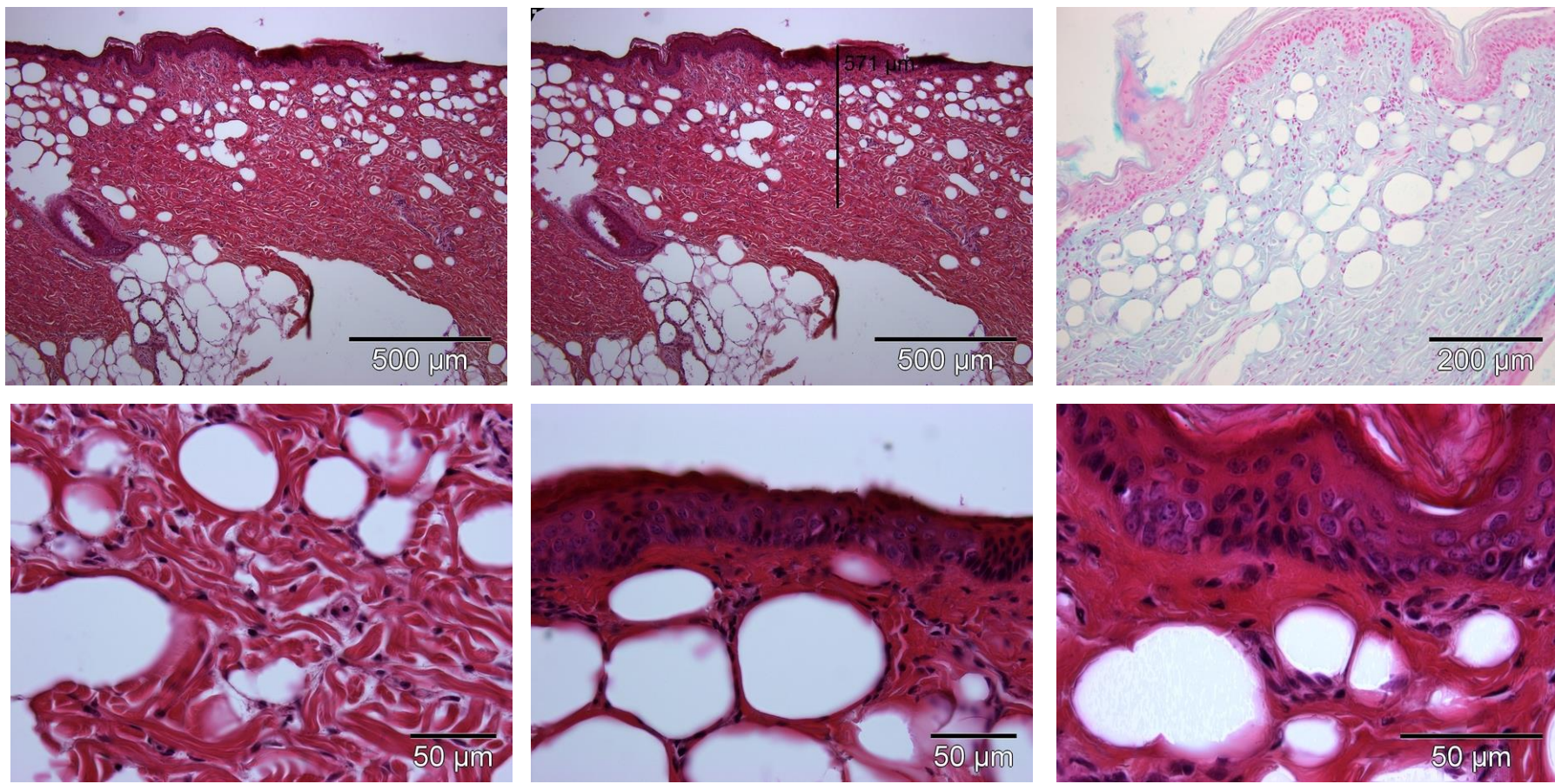
- Liver focal horizontal ablation of the epidermis and assumptions of HA
- Small to medium-sized volumes transfer between the fiber with "Auffederung", sectional application in large volumes of the deep

# Pneumoporation with high-stream native hyaluronic acid



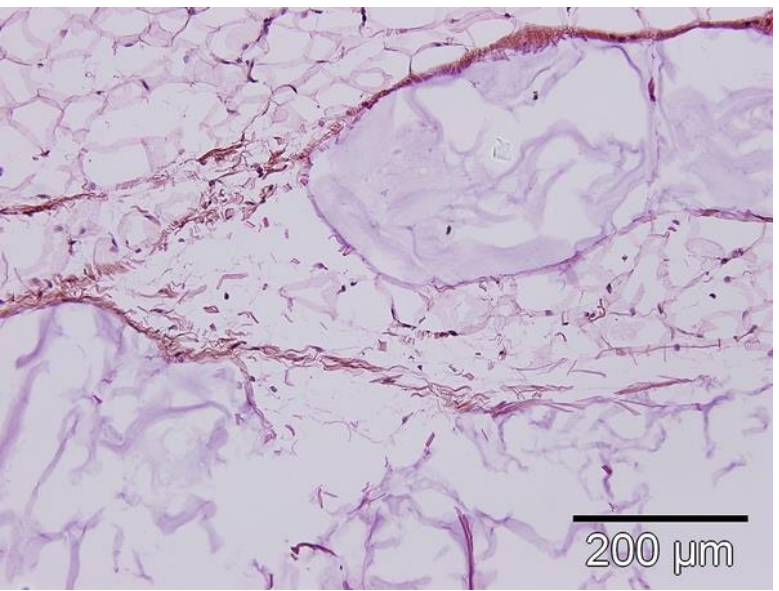
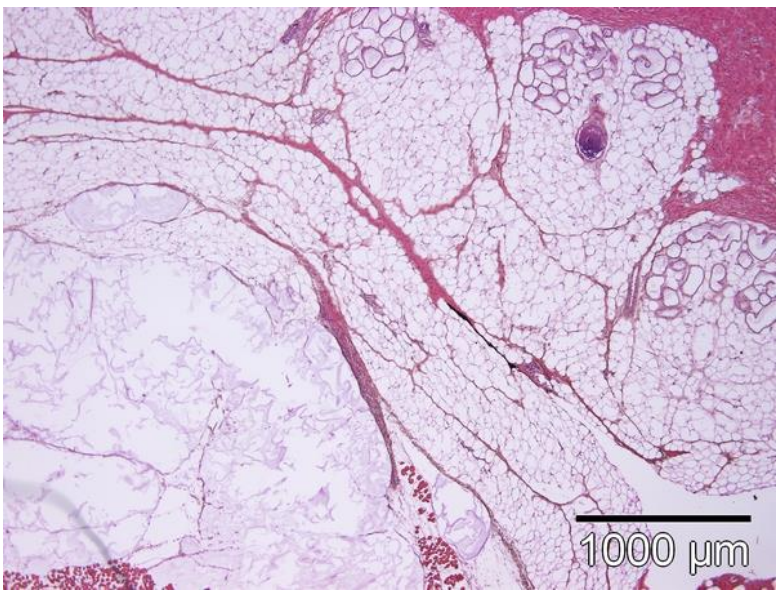
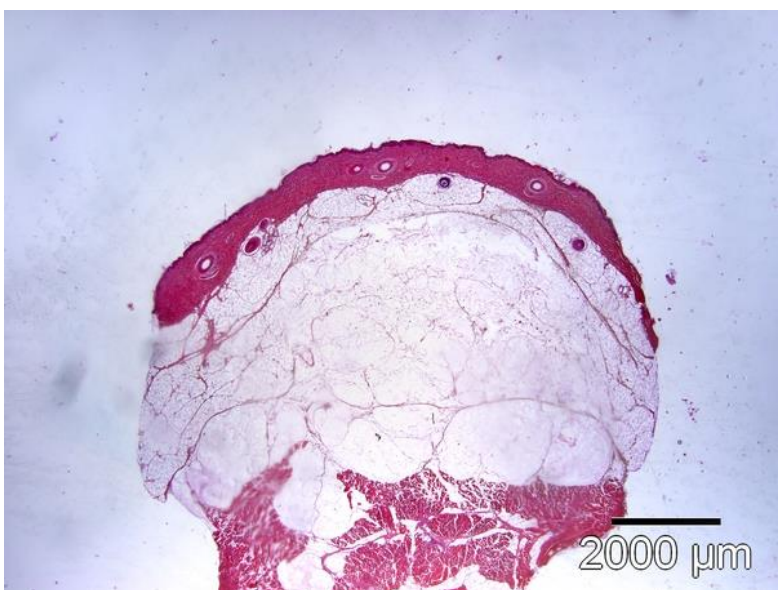
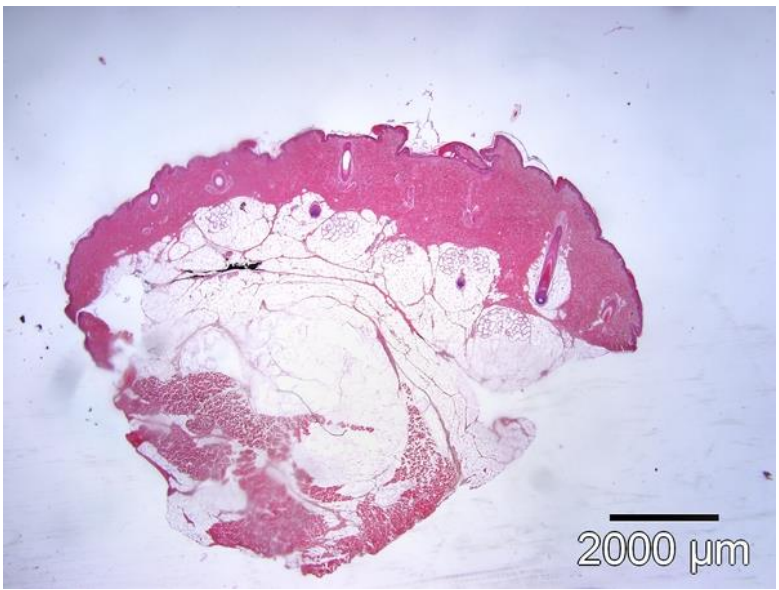
For patients treated liver focal epidermis dermal deposits up to approx. 1mm deep reaching down to fatty tissue

# Pneumoporation with decreased-stream native hyaluronic acid 30s.

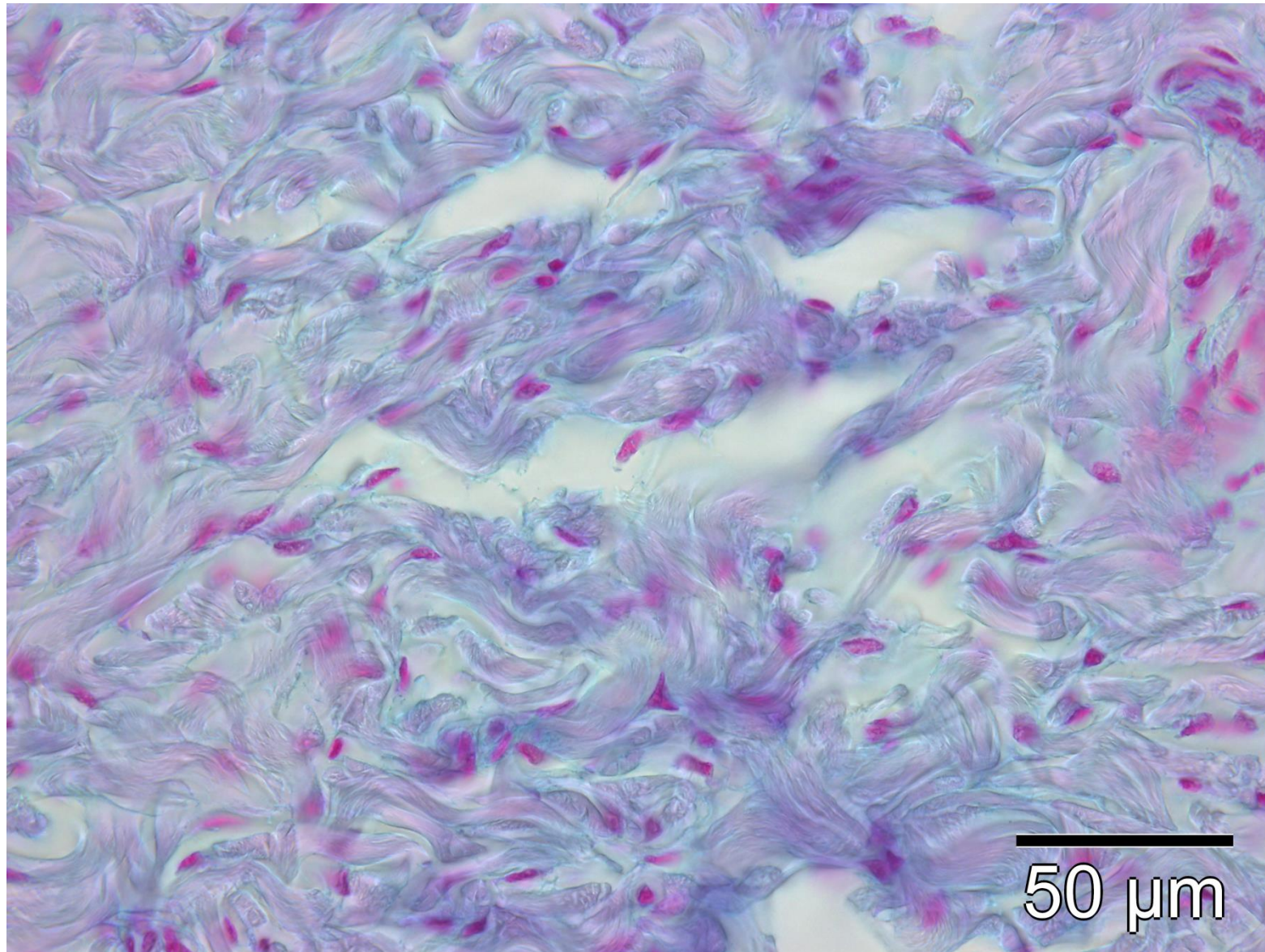


- The targeted application of hyaluronic acid on an area of a few square centimeters over 30s, with decreased stream, results in
- Focal horizontal abrasion of the epidermis and HA deposit
  - Insertion of small to medium volumes between fibers with "feathering"
  - Section-wise in-depth application of large volumes

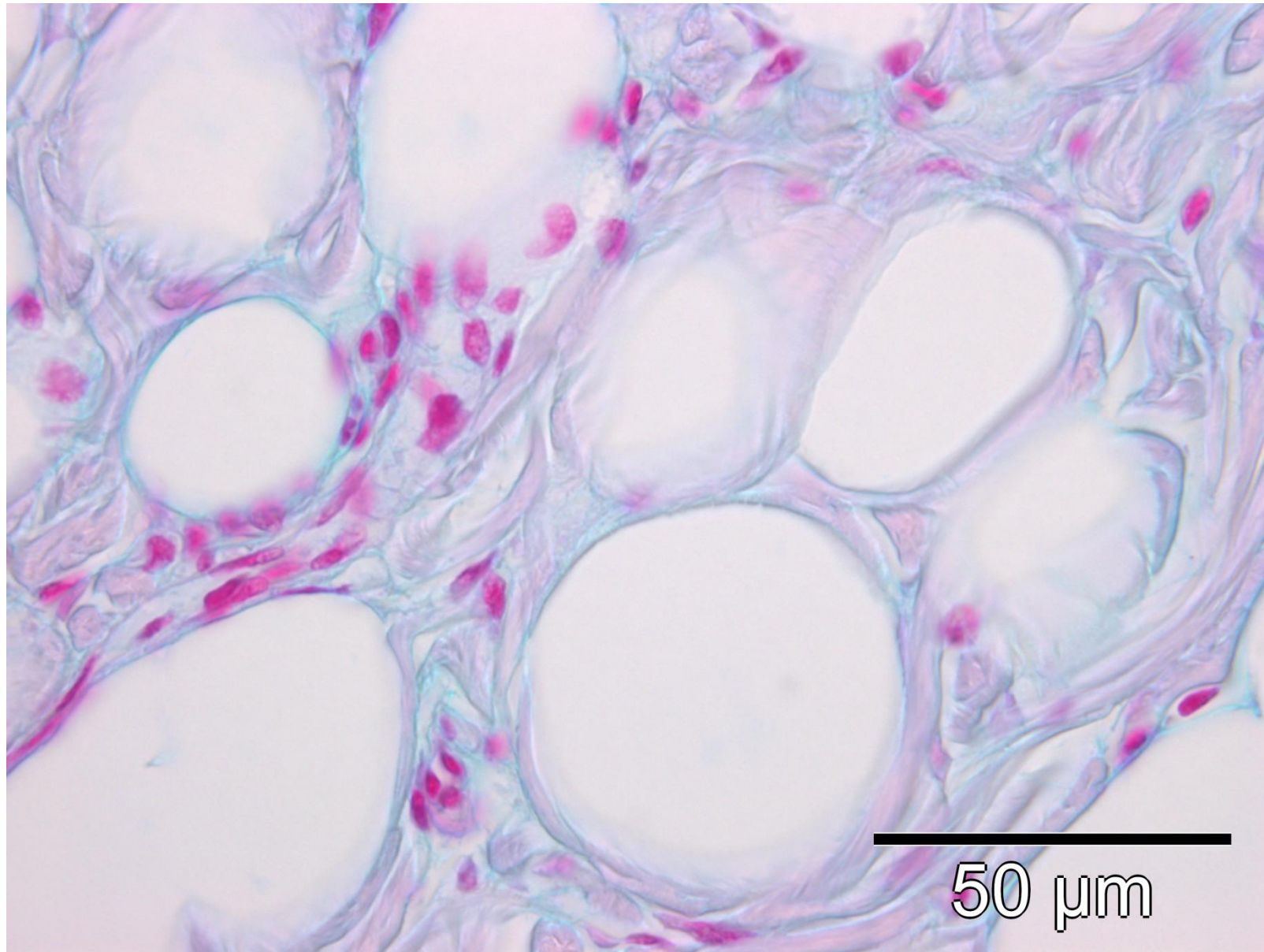
# Comparison with classical injection of low-netted hyaluronic acid



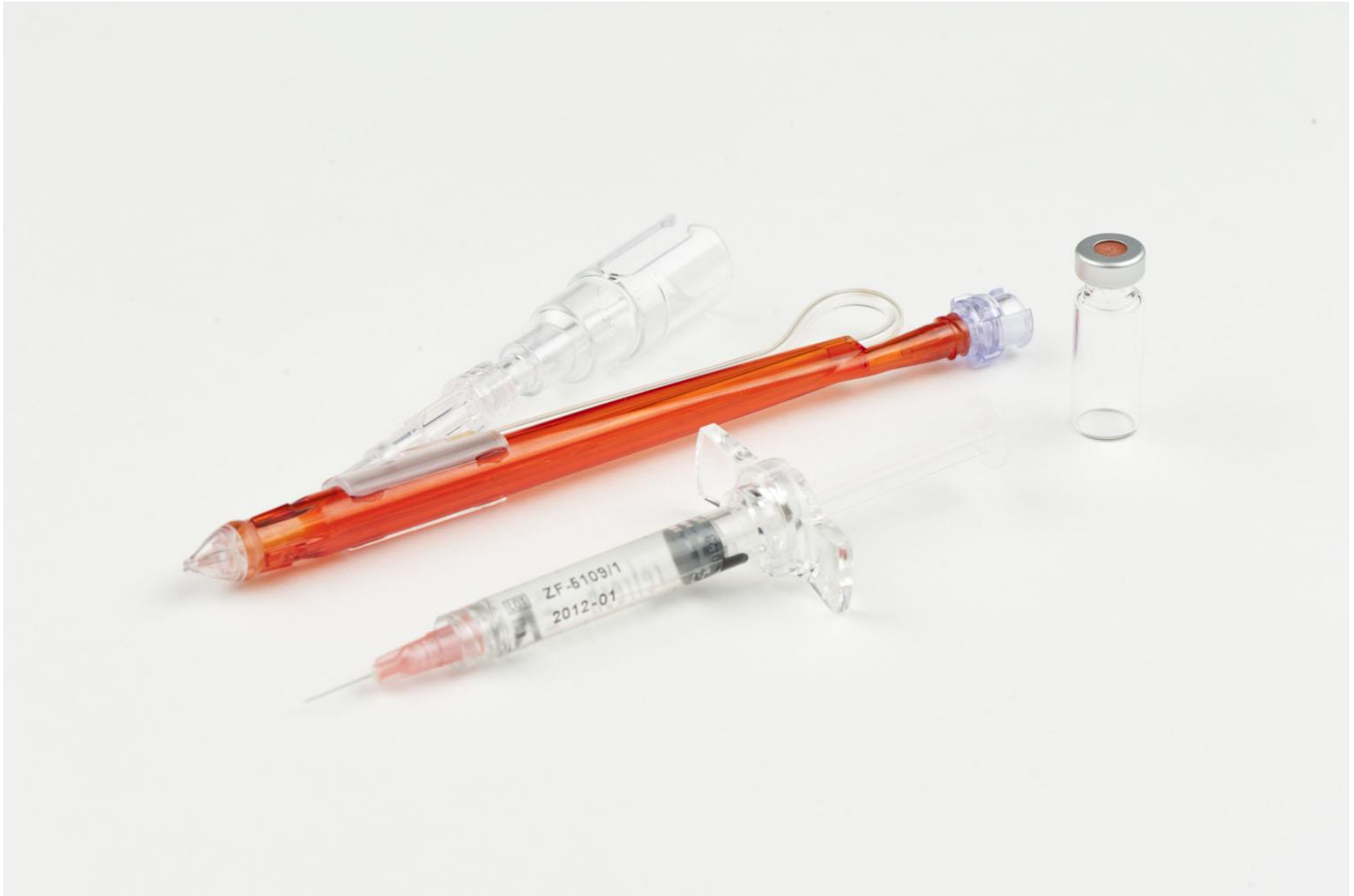# Pneumoporation with native Hyaluronic acid



# Pneumoporation with native Hyaluronic acid

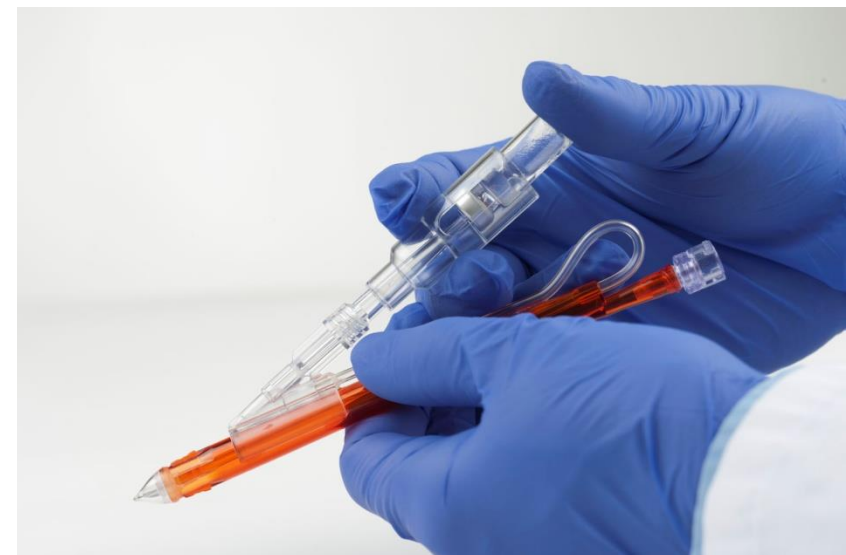
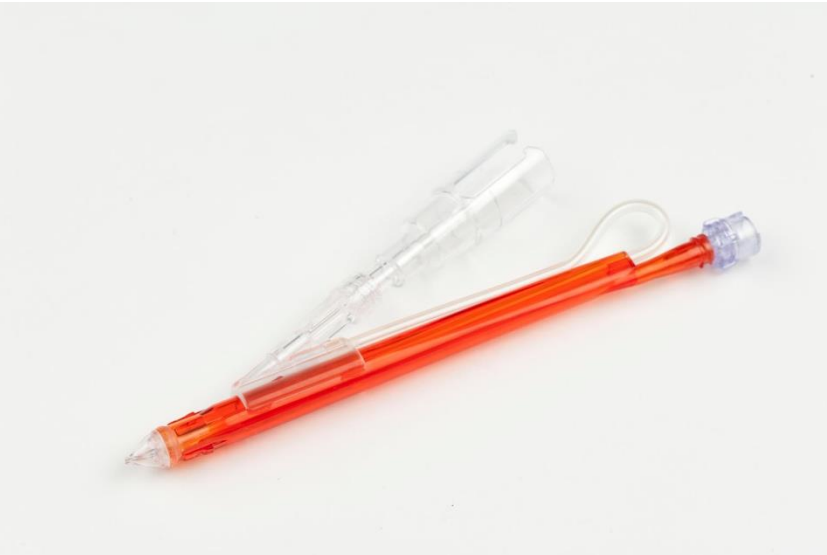
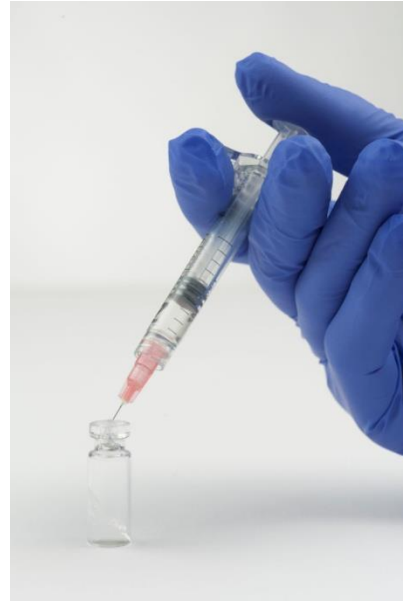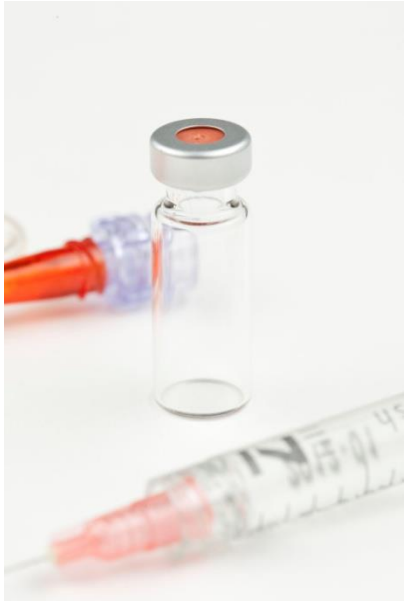# Pneumoporation of high-viscosity substances

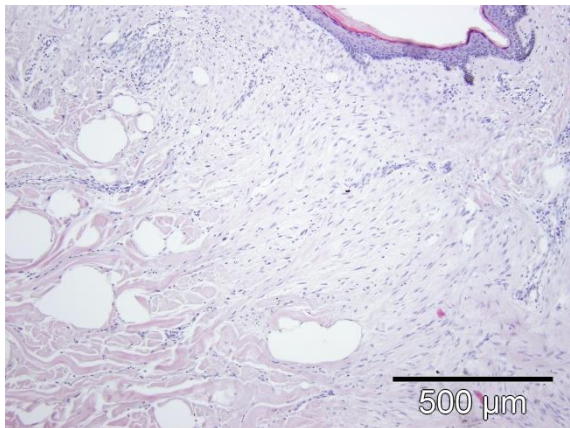
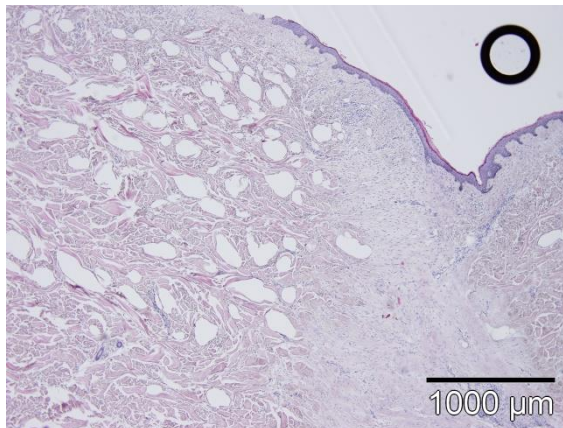
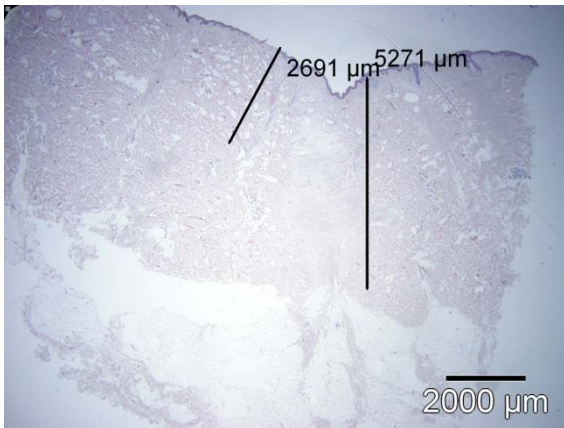
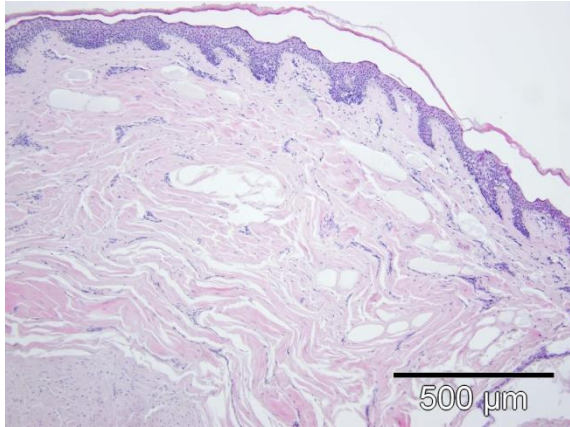
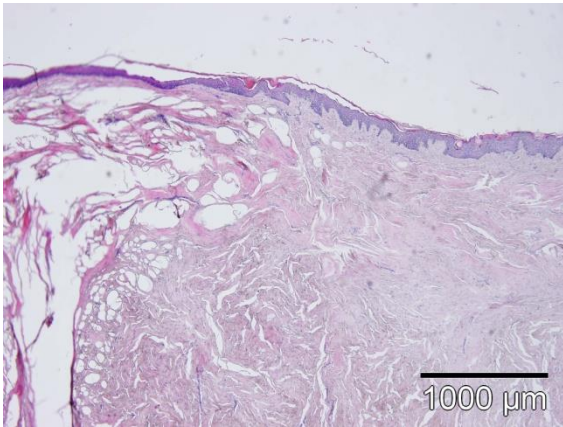
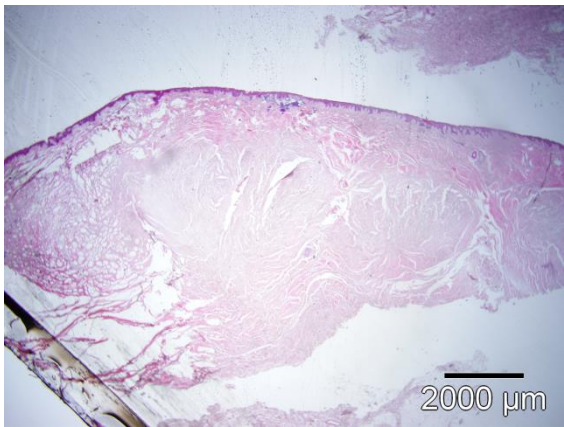




# Pneumoporation of high-viscosity substances

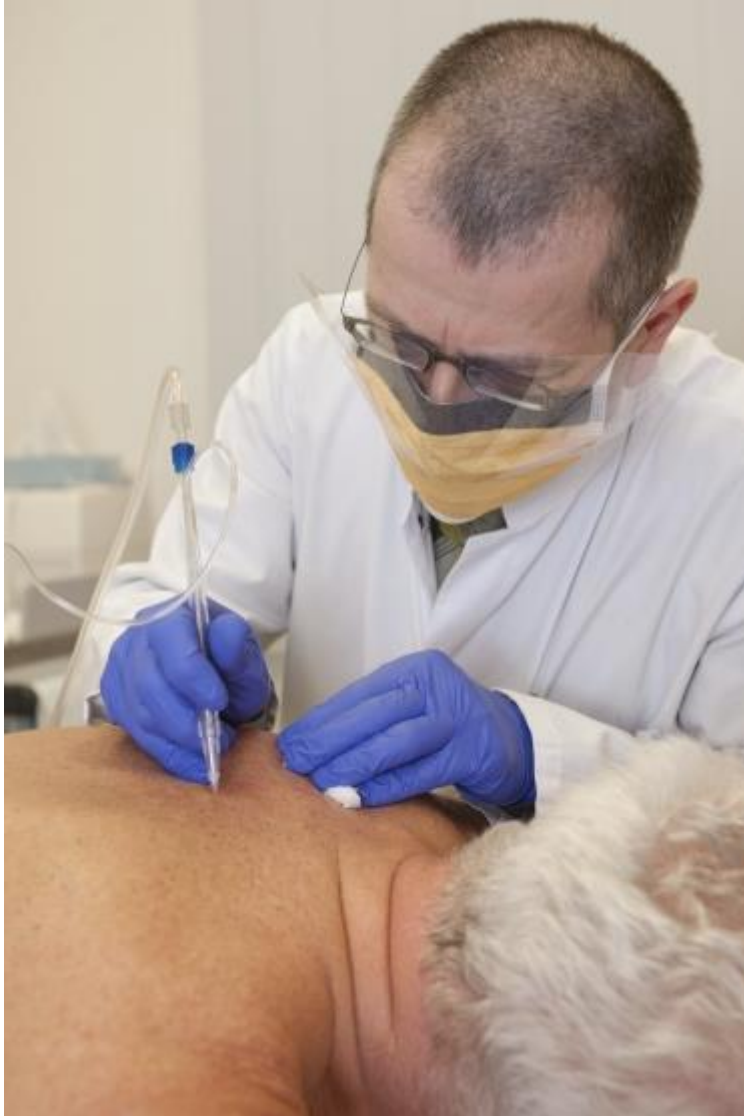

# Pneumoporation of crystalloid substances



The pneumoporation of crystalloid substances (Triamcinolon) is possible continuously without blockage  
Penetration verifiable down to 2.5 mm in normal conjunctive tissue  
Reduced penetration in scar tissue  
Edge penetration only in keloids

# Safety, after-care



Eye protection for patient and physician

Correct indication

Information as to

- Emphysema,
- HSV,
- Infections,
- PIH,
- Scars

Preparation

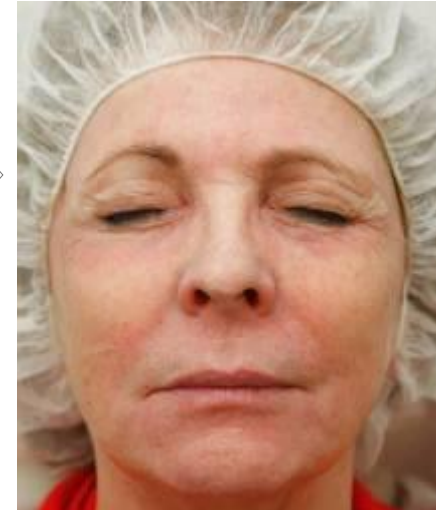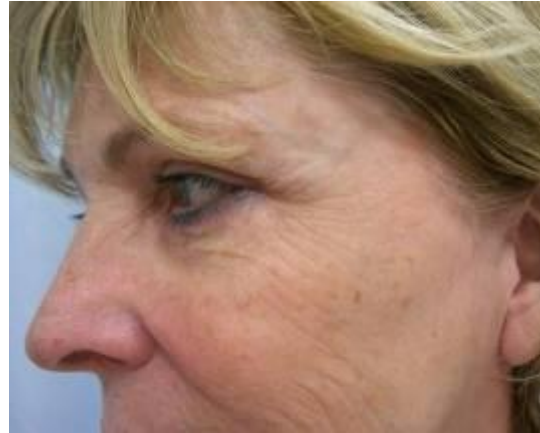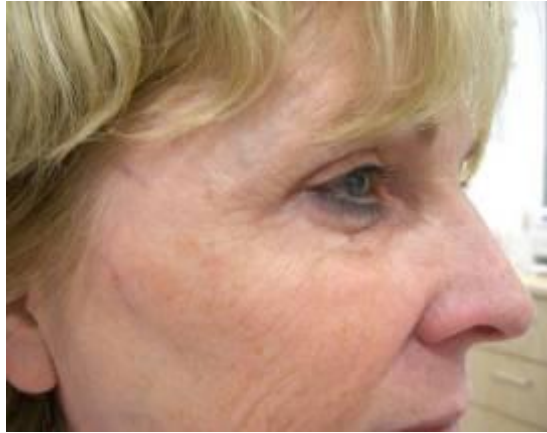- Desinfection
- Flow verification
- Degreasing
- Vaporization
- Peeling

Application of an after-care regimen

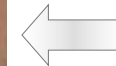
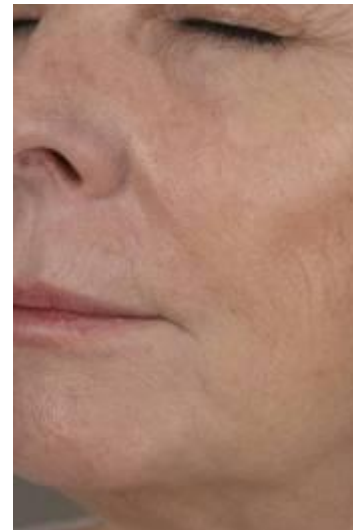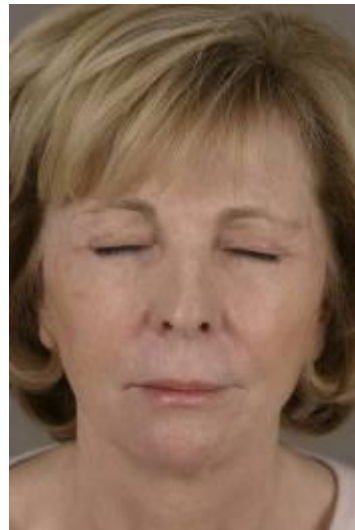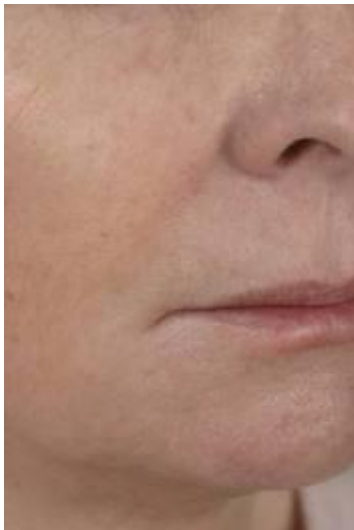- Cooling
- Replenishing
- Care

# Conception

**Before  
Tx**



**After  
4 Tx**



## Hydro und pneumoporation is safe and effective

- Hydrodermabrasion
- Hydrocomedolysis
- Hydroporation of substances
  - Dissolved (fluid)
  - Crystalloid
  - Low viscosity
  - High viscosity
  - Macromolecules

## Potential for dermatological implementation Rosacea

- Rosacea
  - Mb. Morbihan
- Acne
- Esthetics
  - Wrinkles, PIH, texture, pores
  - Striations
  - Alopecia
- Scars
- Targeted disease control
  - WSC Hedhog Inhibitors
  - PDT
  - Local antibody, Capsosome, Polydextrin or PEG deposition

## Potential combinations

- Water-absorbable lasers
- RF

---

**Thank you**