

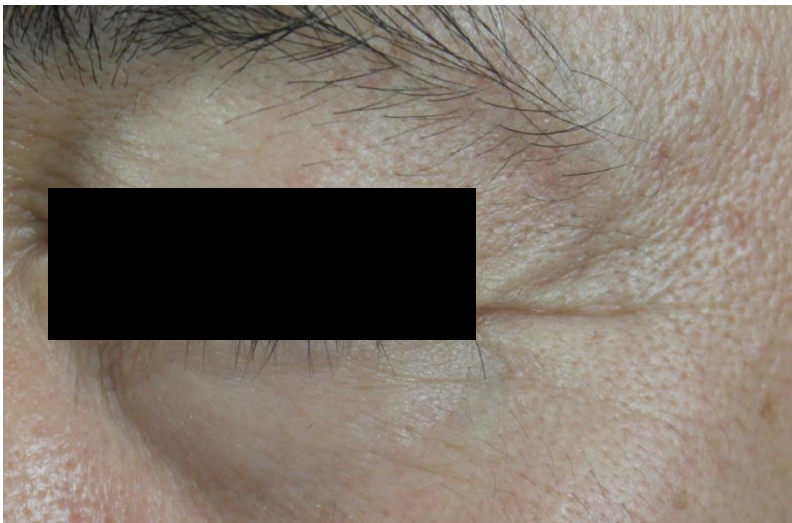
# Histology Results Following JetPeel Treatment

Dr. Kyong-Chan Park

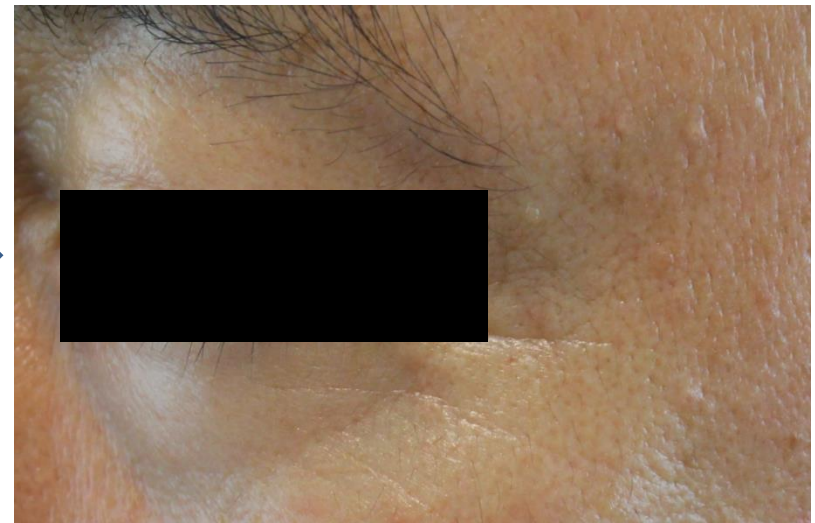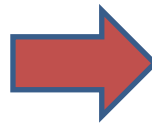
Professor in Dept. of Dermatolog  
y at SNUH

# Case

- A male aged 59 years
- Treated with Jet-M containing cosmetic preparation once a week for 12 weeks
- **Wrinkles** around the treated eye were greatly **decreased**



Before

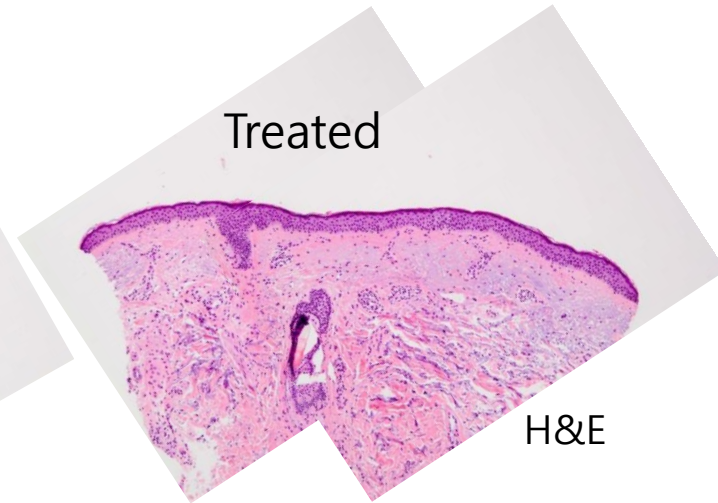
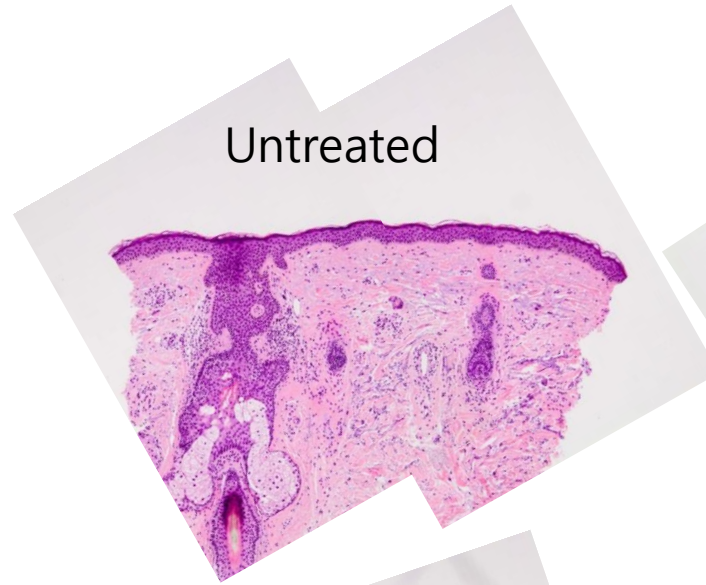


12 weeks later

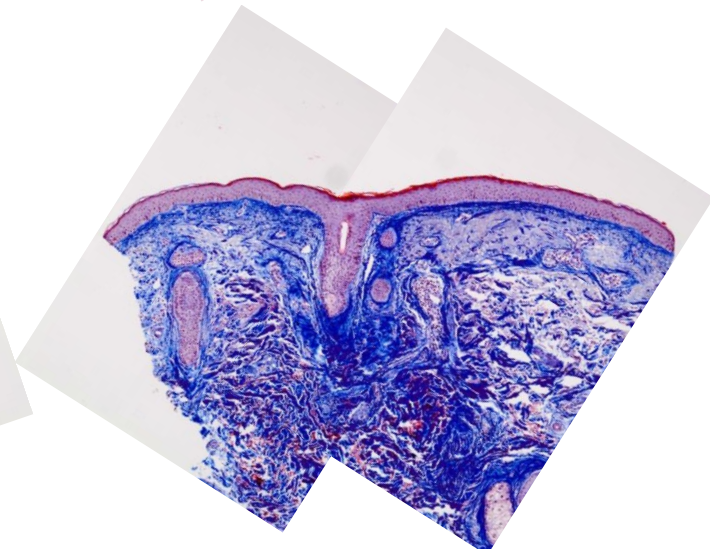
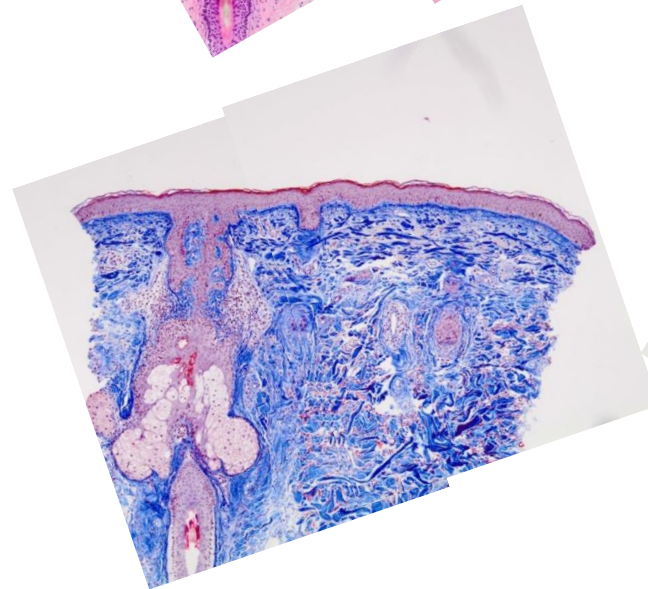
- Collagen fiber

- H&E

- Masson's trichrome



H&E



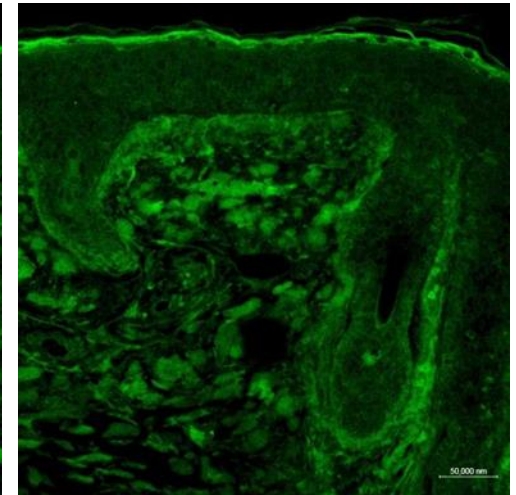
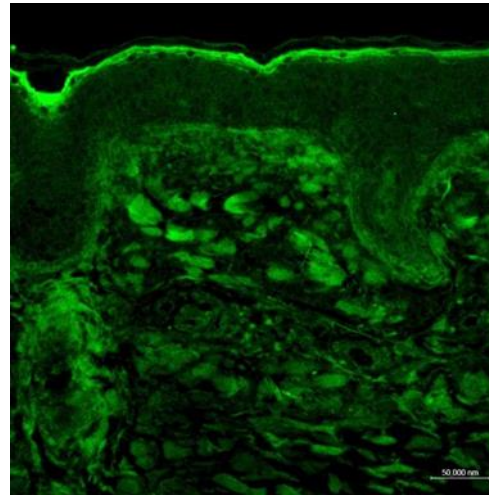
Masson's trichrome

**-> Collagen was increased in the upper dermis**

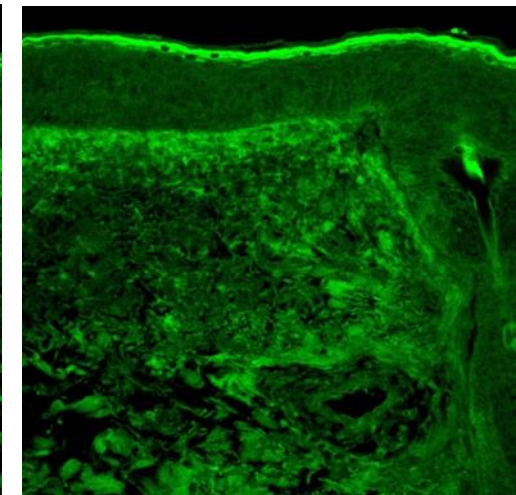
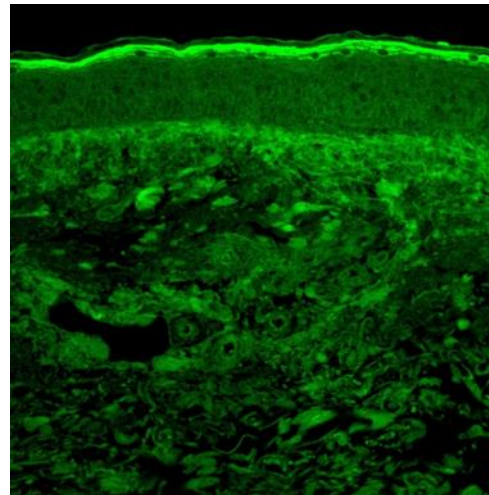
- Fibrillin-1

- IF staining using antibody
- Green: Fibrillin-1 (mouse Ab)

Untreated



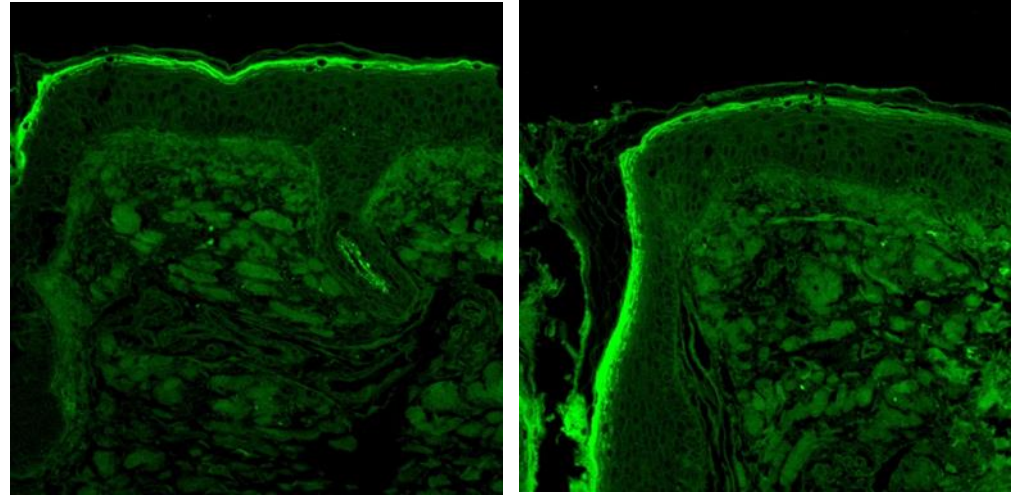
Treated



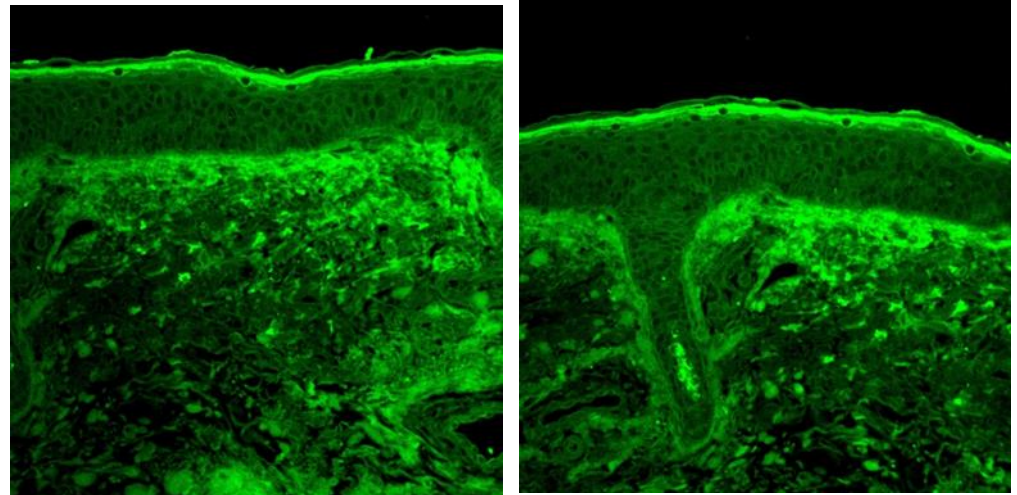
-> Fibrillin-1 was greatly increased in the upper dermis

- Procollagen type 1
- IF staining using antibody
- Green: Procollagen type 1 (mouse Ab)

Untreated



Treated

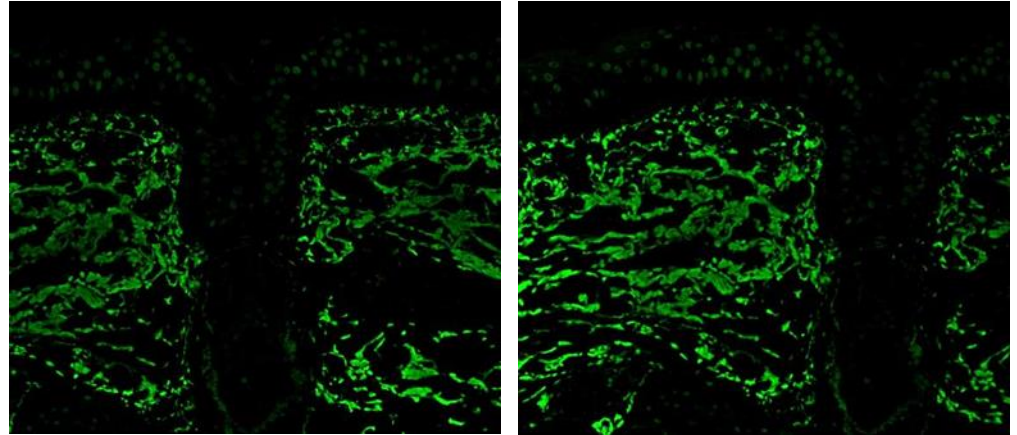


-> Procollagen type 1 was also greatly increased in the upper dermis

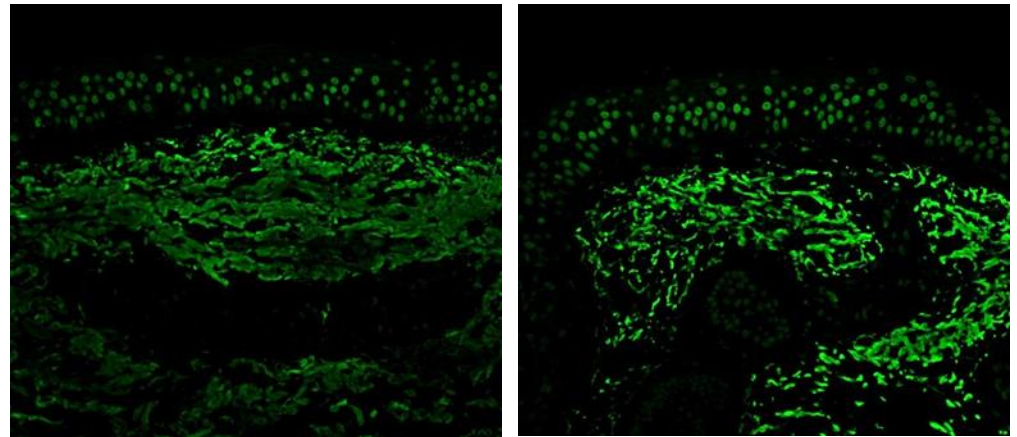
- Tropoelastin

- IF staining using antibody
- Green: Tropoelastin (rabbit Ab)

Untreated



Treated



-> Tropoelastin was also increased in the upper dermis

## Results

By triple-jet treatment for 12 times with Skin-MD solution,

- 1) Wrinkle is decreased around eye.
- 2) Collgen amount is increased.
- 3) Fibrillin-1 was also increased.
- 4) Type 1 collagen was increased.
- 5) Tropoelastin was increased.

# Preliminary clinical study from 6 volunteers

	V1	V2	V3
MI	178.72	171.17	165.94
SD	17.22	18.86	18.98
EI	285.72	277.33	269.67
SD	49.03	39.46	39.91

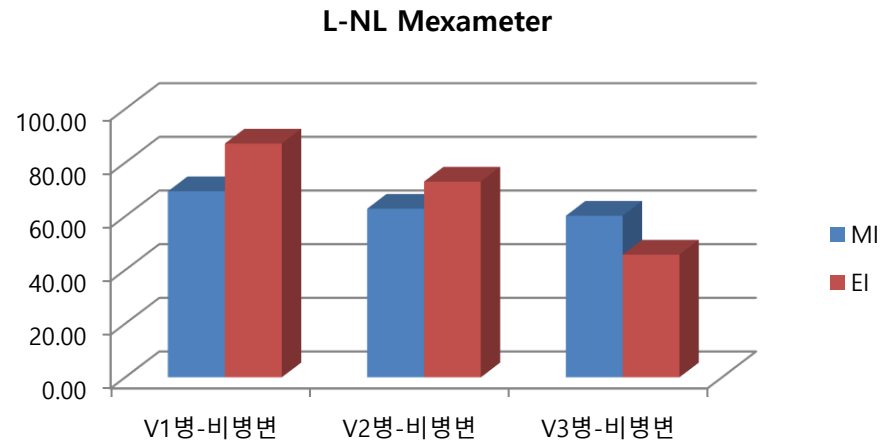
Lesional MI and EI

	V1	V2	V3
MI	109.39	108.33	105.72
SD	14.33	15.82	13.76
EI	198.61	204.39	223.94
SD	31.48	32.10	42.24

Non-lesional MI and EI

	V1	V2	V3
MI	69.33	62.83	60.22
SD	15.49	19.75	19.52
EI	87.11	72.94	45.72
SD	33.61	19.23	41.82

Lesional – non-lesional MI and EI





## Results

By triple-jet treatment for 8 times with Skin-MD solution,

- 1) Melanin index was decreased significantly.
- 2) However, changes of erythema index (EI) was more significant.

## Summary

- Triple-jet treatment for 8 times with Skin-MD solution is effective not only in pigmentation but also in facial erythema.