

The effects of hydroporation on melasma with anti-aging cocktail

Je Byeong Chae MD^{1,2}  | Seung Hye Yang MS² | Sang Young Byun MD^{1,2} |
Hye-Ryung Choi PhD² | Jung-Won Shin MD^{1,2} | Kyoung-Chan Park MD PhD^{1,2}

¹Department of Dermatology, Seoul National University College of Medicine, Seoul, Korea

²Seoul National University Bundang Hospital, Seongnam, Gyeonggi, Korea

Correspondence

Kyoung-Chan Park, Department of Dermatology, Seoul National University Bundang Hospital, Seongnam, Gyeonggi, Korea.

Email: gcpark@snu.ac.kr

Funding information

Korean Health Technology R&D Project, Ministry of Health & Welfare, Republic of Korea, Grant/Award Number: HN14C0094.

Summary

Background: Jet-M is a device for epidermal peeling and is used to deliver substances by spraying air and microdroplets. Previously, a case was treated with a mixed solution of copper-GHK, oligo-hyaluronic acid, Rhodiola extract, tranexamic acid, and β -glucan. The results showed significant improvement of aged skin.

Aims: This study was conducted to evaluate the effects of hydroporation on melasma with the formulation in a small group of volunteers.

Methods: Clinical effects were evaluated by both subjective and objective methods including melanin index (MI) and erythema index (EI) measurement.

Results: Clinically, pigmentation and erythema were relieved and also both MI and EI decreased. Histopathologic observation revealed that type IV collagen and procollagen were increased in the upper dermis. Furthermore, the number of p63-positive cells is increased along the basement membrane. These results all suggest that hydroporation with GHR formulation induced anti-aging effects by reconstruction of extracellular matrix.

Conclusion: These findings suggest that the treatment may have depigmenting effects and erythema decreasing effects by enhancing the microenvironment of the skin.

KEYWORDS

basement membrane, collagen, hydroporation, Jet-M, melasma

1 | INTRODUCTION

JetPeel (Tav-Tech Ltd., Yehud, Israel) is a skin resurfacing device to perform mechanical peeling and stretching of the superficial skin by spraying air and microdroplets. The device accelerates the flow of air and liquid to a subsonic speed, in which liquid is converted into microdroplets by the force of turbulence.¹ Jet-M, an improved version of JetPeel-2, utilizes a compressor unit. Thus, Jet-M can deliver liquid substances into the epidermis and even into the dermis. Paash et al. suggested the term "hydroporation" to describe procedures that incorporate subsonic flow of air and microdroplets.²

In brief, the key functions of Jet-M are superficial skin exfoliation and trans-dermal delivery. Recently, we reported a case of a man who received hydroporation treatment with a mixed solution containing copper-GHK, oligo-hyaluronic acid, rhodiola extract, tranexamic acid and β -glucan (GHR formulation), once a week for a total

duration of 12 weeks. He showed significant improvements clinically and histologically.³

Melasma is a common hypermelanosis that frequently appears on the face. Histopathologic features of melasma include solar elastosis, disrupted basement membrane, increased vascularity and epidermal pigmentation. These findings suggest that dermal structural alteration may have an important role in the pathogenesis of melasma. Thus, we tried to evaluate the effects of Jet-M with GHR formulation on melasma.

2 | MATERIALS AND METHODS

2.1 | Hydroporation

Six volunteers with melasma were recruited and informed about the treatment. They were treated by Jet-M with a GHR formulation once a week for 8 weeks. The treatment involved a two-stage

procedure. First, air and saline were delivered 1cm away from the surface of the face for epidermal peeling. Second, the whole face was treated with GHR formulation, while the headpiece was moving at 2cm/s by the operator, and the spurt pressure was set to 95psi.

2.2 | Clinical evaluation

Clinical evaluation was carried out before, 4 weeks, and 8 weeks after the treatment. For subjective evaluation, two dermatologists observed the lesion and estimated the degree of skin changes. The clinical manifestations were graded on a 5-point scale (5; very severe, 4; severe, 3; moderate, 2; mild, and 1; very mild).

2.3 | Melanin index (MI) and erythema index (EI)

For a more objective assessment, MI and EI were measured with Mexameter MX-18 (CK electronic GmbH, Germany). MI was measured on the hyperpigmented lesion, and EI was measured on the flushing lesion. To minimize interpersonal and intrapersonal variations, MI and EI on the normal skin area (pre-auricular area) were also evaluated, and relative MI and relative EI were calculated.⁴

2.4 | Immunohistochemistry and image analysis

To evaluate histological changes, 2 mm punch biopsy specimens were obtained from the lesional skin of six volunteers, before and 8 weeks after treatment. Masson's trichrome staining was performed to visualize the amount of collagen fibers. To assess the integrity of basement membrane, immunohistochemical staining with 1:100 diluted rabbit polyclonal antibody to type IV collagen was performed. Basal cell stemness was evaluated by staining keratinocytes with an anti-p63 antibody diluted 1:50 (Both of them from Abcam, Cambridge, UK).⁵ To visualize procollagen, a mouse IgG1 to procollagen type I (1:500 dilution, DSHB, Iowa, USA) was used. All the images were analyzed using an image analysis program (MetaMorph® Microscopy Automation & Image Analysis Software; Molecular Devices, Sunnyvale, CA, USA). At 200× magnification, ten circular

areas with same diameter were selected and the average stained areas were determined in every volunteer.

2.5 | Statistical analysis

Data were analyzed statistically using a Wilcoxon test, and *P*-values of <.05 were considered as statistically significant.

3 | RESULTS

3.1 | Clinical evaluation

All volunteers completed the study. Every 4 weeks, photographs were taken and evaluated by two dermatologists. The degree of pigmentation and erythema was graded on a 5-point scale. Before the treatment, average degree of pigmentation was 3.167 and 2.667, respectively. At the end of the study, the average decreased to 2.5 and 2.167, respectively. Likewise, the estimated degree of erythema was 2.83 and 2.5, respectively, which decreased to 1.83 and 1.83 after treatment.

For a more objective evaluation, MI and EI were measured. Before the treatment, MI was 178.72 ± 17.22 . Then, it decreased to 171.17 ± 18.86 and 165.94 ± 18.98 after 4 weeks and 8 weeks, respectively. Initial EI was 285.72 ± 49.03 . It also decreased to 285.72 ± 39.46 and 269.67 ± 39.91 after 4 weeks and 8 weeks, respectively. To reduce the variations among different individuals, sites, and seasons, we incorporated "relative MI" and "relative EI" (MI at site/MI at pre-auricular area, EI at site/EI at pre-auricular area).⁶ Before treatment, relative EI was 1.45 ± 0.16 . It decreased to 1.36 ± 0.11 and 1.23 ± 0.23 at 4 weeks and 8 weeks, respectively (*P*=.046). Relative MI was 1.65 ± 0.19 at the start of treatment, which decreased to 1.60 ± 0.24 and 1.58 ± 0.23 at 4 weeks and 8 weeks, respectively (*P*=.075). (Figure 1, Table 1).

3.2 | Histological evaluation

Skin biopsy was performed before and 8 weeks after the treatment. The specimens were stained and analyzed with image analysis software, as previously described. There were no significant differences

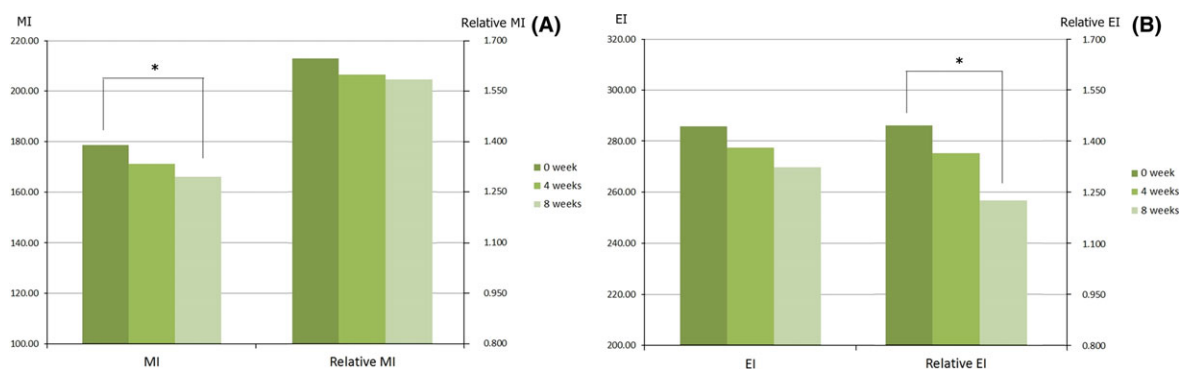


FIGURE 1 The changes of MI and relative MI (A) as well as changes of EI and relative EI (B). All parameters have a tendency to decrease with treatment of hydroporation with GHR formulation; MI and relative EI have statistical significance. **P*<0.05 in comparison to the pretreatment state (*P*-value; MI=0.028, relative MI=0.075, EI=0.463, relative EI=0.046)

TABLE 1 Degree of pigmentation and erythema of six volunteers were evaluated by two dermatologists. Both pigmentation and erythema got improved after 8 weeks of treatment, and it was statistically significant except pigmentation by doctor 2. MI and EI measured with Mexameter, and they show tendency of decreasing. MI and relative EI were significantly decreased after treatment

| n=6 | 0 week | 8 week | P value |
|------------------------|--------------|--------------|---------|
| Degree of pigmentation | | | |
| Doctor 1 | 3.17±0.75 | 2.50±0.55 | .046* |
| Doctor 2 | 2.67±0.52 | 2.17±0.75 | .083 |
| Degree of erythema | | | |
| Doctor 1 | 2.83±0.75 | 1.83±0.75 | .034* |
| Doctor 2 | 2.50±0.84 | 1.83±0.75 | .046* |
| MI | 178.72±17.22 | 165.94±18.98 | .028* |
| EI | 285.72±49.03 | 269.67±39.91 | .463 |
| Relative MI | 1.65±0.19 | 1.58±0.23 | .075 |
| Relative EI | 1.45±0.16 | 1.23±0.23 | .046* |

*Wilcoxon test, statistically significant; $P < .05$.

in H&E staining. However, there were increased collagen fibers in the upper dermis with Masson's trichrome staining. (Figure 2A,B) Immunohistochemical staining showed that type IV collagen expression was remarkably increased in the basement membrane area and procollagen expression was also increased in the upper dermis and basement membrane area. Likewise, there were more keratinocytes that express p63 in the basement membrane area (Figure 2C-H).

The calculated stained area significantly increased from 7.92 ± 1.08 to 13.83 ± 3.46 in type IV collagen staining and from 51.64 ± 10.69 to 84.75 ± 17.98 in procollagen staining, respectively. The stained area of p63 was also significantly increased along the basement membrane from 20.379 ± 6.36 to 31.456 ± 6.717 (Figure 3).

4 | DISCUSSIONS

JetPeel was developed for gentle cosmetic peeling of the facial skin. It can create a jet stream composed of microdroplets and gas. The subsonic flow can exfoliate the epidermis and even reach the upper dermis.¹ The effects of these devices were reported in several clinical studies. In 2011, Iannitti et al. reported that JetPeel™-3-mediated anesthesia was more effective than EMLA cream administration ($P < .001$).⁷ In 2014, Iannitti et al. also reported that JetPeel™-3 can deliver both anesthetics and BTX-A at the same time with less pain and higher patient satisfaction.⁸ These studies suggested that JetPeel devices with a compressor system can effectively and conveniently deliver small molecules onto the skin. Paash et al. performed an in vitro study to prove the penetration ability of "hydroporation" and patterns of deposition according to molecular size. Low molecular weight particles showed a homogenous distribution with a depth of up to the dermal layer; conversely, high molecular weight particles (more than 2kDa) were unable to penetrate the epidermal barriers.²

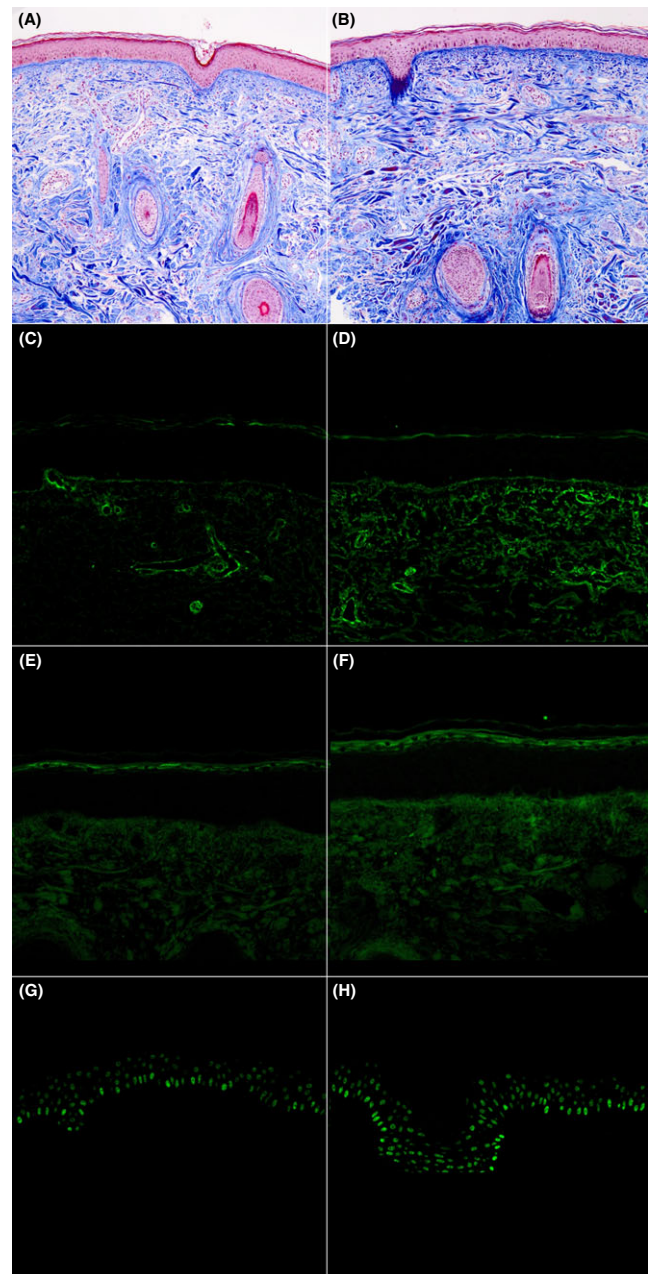


FIGURE 2 Histological changes after 8 weeks of treatment. Masson trichrome staining shows increased collagen fibers in the upper dermis (A, B). In immunohistochemical stainings, procollagen (C, D) and type IV collagen (E, F) levels increased in the upper dermis and basement membrane area. The p63-positive cells are also increased along the basement membrane (G, H). ($\times 200$)

Melasma is a hypermelanotic skin condition usually presenting with brown-colored macules on sun-exposed areas. Although melasma is considered as the one of the epidermal pigmentation disorders, it has characteristic dermal histological features in common.⁹ Dermal extracellular matrix abnormalities, such as solar elastosis, are frequently observed in lesional melasma skin compared with perilesional skin.^{10,11} Basement membrane disruption is an additional finding for melasma.¹⁵ It is thought that chronic ultraviolet (UV) radiation exposure induces basement membrane disruption.¹²

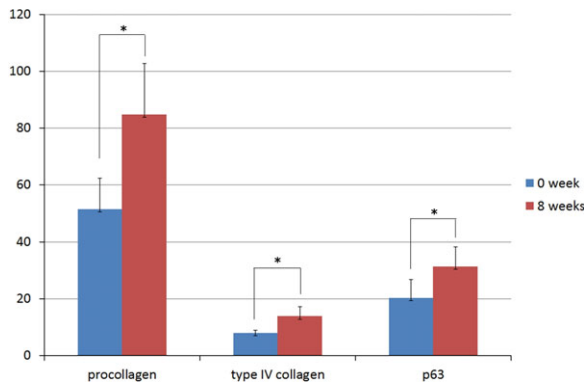


FIGURE 3 The calculated area of immunohistochemical staining before and after treatment. Procollagen, type IV collagen, and p63 levels in the basement membrane area were significantly increased. * $P < 0.05$, by Wilcoxon test (P -value; procollagen=0.043, type IV collagen=0.028, p63=0.043)

Furthermore, melasma skin lesion shows increased number of blood vessels, vessel density, and vessel size compared with perilesional skin.¹³ From these histological findings, melasma can be regarded as one of the phenotypes of photodamaged skin, rather than one of the epidermal pigmentation disorders. Therefore, improving the damaged and photo-aged skin with anti-aging cocktail hydroporation might be helpful in melasma treatment.

TABLE 2 Clinical evaluation was performed by two dermatologists with 5-point scale

| | Doctor 1 | | Doctor 2 | | Pigmentation | Doctor 1 | | Doctor 2 | |
|-----------|----------|---------|----------|---------|--------------|----------|---------|----------|---------|
| | 0 week | 8 weeks | 0 week | 8 weeks | | 0 week | 8 weeks | 0 week | 8 weeks |
| Patient 1 | 3 | 2 | 3 | 2 | Patient 1 | 3 | 2 | 3 | 2 |
| Patient 2 | 3 | 2 | 3 | 3 | Patient 2 | 2 | 2 | 2 | 1 |
| Patient 3 | 4 | 2 | 3 | 2 | Patient 3 | 4 | 3 | 3 | 3 |
| Patient 4 | 2 | 1 | 2 | 1 | Patient 4 | 3 | 2 | 2 | 2 |
| Patient 5 | 3 | 3 | 3 | 2 | Patient 5 | 3 | 3 | 3 | 2 |
| Patient 6 | 2 | 1 | 1 | 1 | Patient 6 | 4 | 3 | 3 | 3 |

5; very severe, 4; severe, 3; moderate, 2; mild, and 1; very mild.

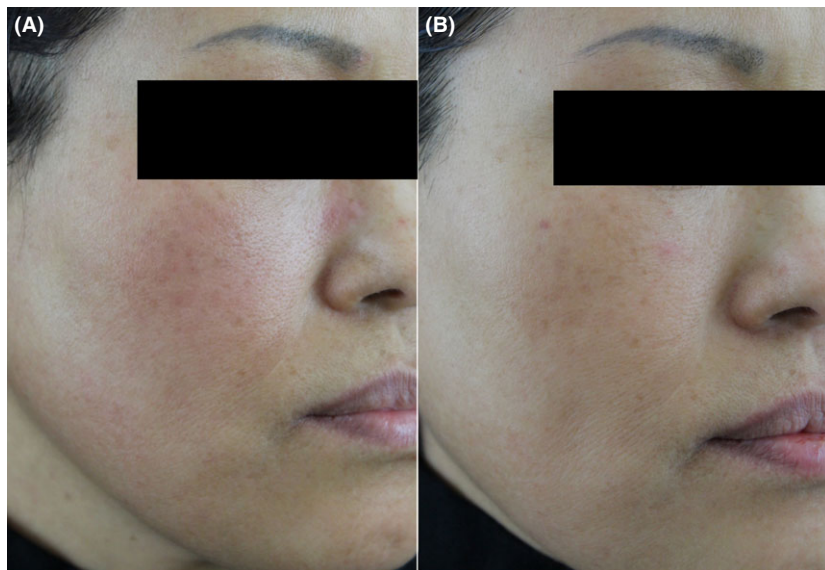


FIGURE 4 Clinical photograph of a volunteer at before (A) and after 8 weeks (B) of treatment. The erythematous lesion on the cheek had dramatically reduced

In this study, the clinical and histological efficacy of a GHR formulation combined with a hydroporation device was verified. GHR formulation contained copper-GHK, oligo-hyaluronic acid, *Rhodiola* extract, tranexamic acid, and β -glucan, which were selected according to the evidences from the former dissertations. Glycyl-L-histidyl-L-lysyl (GHK) spontaneously forms a complex (copper-GHK) with copper ion through its high affinity, and copper-GHK promotes wound healing by boosting collagen synthesis.¹⁴ Oligo-hyaluronic acid was reported to induce epidermal thickening in the skin equivalent model.¹⁵ *Rhodiola* extract has active compounds, including *p*-coumaric acid, catechin, and *p*-tyrosol. Among them, *p*-coumaric acid has been shown to have a significant inhibitory effect on melanogenesis through competitive inhibitory activity with tyrosine.¹⁶ Tranexamic acid might reduce the pigmentation in melasma patients by reducing the vascularity and mast cell numbers.¹⁷ Lastly, β -Glucan seems to act as an antioxidant and plays a role in antiwrinkling, anti-ultraviolet light, and wound healing.¹⁸ Accordingly, we can expect anti-aging and hypopigmenting effects in aged skin of melasma by restoring dermal and epidermal deformities with multiple mechanisms of our formulation.

In our former case report, a man was treated using Jet-M with GHR formulation once a week for 12 weeks. Fine wrinkles at the corner of the eye (crow's feet) decreased significantly. Histological

findings also showed a dramatic increase in collagen production. Moreover, fibrillin-1 and procollagen type 1 were also increased significantly.³ These findings suggest that Jet-M with GHR formulation may be a good and safe strategy for anti-aging of the skin.

In this report, a small number of volunteers were recruited and treatment was performed for 8 weeks. Subjective evaluation was performed by two dermatologists with clinical photographs. In terms of pigmentation, half of the volunteers showed improvement, while the other half showed no significant changes. Likewise, erythema was found to be decreased in two-thirds of volunteers (Table 2, Figure 4). To assess the differences between the treated and untreated lesions more objectively, MI and EI were measured. As a result, both MI and EI show tendency of decreasing. Furthermore, to reduce the unintended variations, relative MI and relative EI were also measured and relative EI was significantly decreased ($P=.046$). Although the changes of relative MI were not statistically significant ($P=.075$), it may come from the small size of study if considering the number of volunteers.

Then, we performed immunohistochemical staining and results showed histological evidences for the clinical effects. Type IV collagen is a member of the collagen superfamily, which can be found in the kidney, lung, testis, and the skin. In the skin, it occurs mainly in the basement membrane.¹⁹ Procollagen is a soluble precursor of collagen formed mostly by fibroblasts. It is well known that there are alterations of the dermal extracellular matrix composition, both in photo-aged and chronologically aged skins.²⁰ These dermal extracellular matrix proteins gradually decrease with age, and such compositional changes are expressed as wrinkle formation and decreased skin elasticity.²¹ Also, it is known that chronic ultraviolet exposure induces the elevation of the matrix metalloproteinase level, which degrades type IV and type VI collagen in the basement membrane.¹² Therefore, basement membrane disruption is considered as the major histopathologic mechanism in melasma. In this study, type IV collagen and procollagen levels in the basement membrane area were significantly increased. The results show that damaged skin can be recovered with hydroporation treatment.

Although melasma is known as an epidermal pigmentary disease, disruption of basement membrane has been reported as described earlier. It means that niche for epidermal stem cells are damaged. To analyze the effects on epidermal stem cells, p63 positivity was analyzed before and after the treatment. A p63 is a marker for representing keratinocyte proliferation potential.⁵ It was found that the p63 positivity increased in response to hydroporation treatment with GHR formulation. Such increase suggests that this procedure may prolong the stemness of basal keratinocytes and improves the photo-aged skin lesion on melasma.

This study has some limitations because it was performed in a small number of volunteers. In addition, we could not exclude the possible interactions between the ingredients among the formulation. To confirm the effects more precisely, further investigations with a large number of cases including placebo group are necessary.

Nowadays, melasma is considered to be a major cosmetic concern. Herein, we evaluated the effects of GHR formulation on the

skin via a hydroporation technique on melasma. The evaluation was performed with respect to both clinical and histological aspects. In our study, most volunteers were satisfied with the procedure. There was clinical improvement in erythema and hyperpigmentation. Moreover, histopathologic analysis suggests hydroporation with GHR formulation may up-regulate the extracellular matrix structural proteins and recover damaged basement membranes. Overall, this study illustrates the clinical and histological improvement of photo-aged skin by incorporating hydroporation therapy with our own formulation.

ACKNOWLEDGMENTS

This study was supported by a grant from the Korean Health Technology R&D Project, Ministry of Health & Welfare, Republic of Korea (grant number: HN14C0094).

REFERENCES

- Golan J, Hai N. JetPeel: a new technology for facial rejuvenation. *Ann Plast Surg.* 2005;54:369–374.
- Paasch U. Epidermal and dermal histological characteristics in response to hydroporation.
- Byun SY, Chae JB, Na JI, et al. Significant improvement in crow's feet after treatment with Jet-M and a mixed solution of copper-GHK, oligo-hyaluronic acid, rhodiola extract, tranexamic acid, and beta-glucan (GHR formulation). *J Cosmet Laser Ther.* 2016;18:293–295.
- Shin JW, Choi SY, Park KC. Ratio of lesional/non-lesional melanin index: a sensitive parameter for the evaluation of skin lightening agents. *J Dermatol.* 2012;39:561–563.
- Yang A, Schweitzer R, Sun D, et al. p63 is essential for regenerative proliferation in limb, craniofacial and epithelial development. *Nature.* 1999;398:714–718.
- Park ES, Na JI, Kim SO, et al. Application of a pigment measuring device—Mexameter—for the differential diagnosis of vitiligo and nevus depigmentosus. *Skin Res Technol.* 2006;12:298–302.
- Iannitti T, Capone S, Palmieri B. Short review on face rejuvenation procedures: focus on preoperative antiseptic and anesthetic delivery by JetPeel-3 (a high pressure oxygen delivery device). *Minerva Chir.* 2011;66:1–8.
- Iannitti T, Palmieri B, Aspiro A, et al. A preliminary study of painless and effective transdermal botulinum toxin A delivery by jet nebulization for treatment of primary hyperhidrosis. *Drug Des Devel Ther.* 2014;8:931–935.
- Kwon SH, Hwang YJ, Lee SK, et al. Heterogeneous Pathology of Melasma and Its Clinical Implications. *Int J Mol Sci* 2016;17.
- Torres-Alvarez B, Mesa-Garza IG, Castanedo-Cazares JP, et al. Histochemical and immunohistochemical study in melasma: evidence of damage in the basal membrane. *Am J Dermatopathol.* 2011;33:291–295.
- Kang WH, Yoon KH, Lee ES, et al. Melasma: histopathological characteristics in 56 Korean patients. *Br J Dermatol.* 2002;146:228–237.
- Inomata S, Matsunaga Y, Amano S, et al. Possible involvement of gelatinases in basement membrane damage and wrinkle formation in chronically ultraviolet B-exposed hairless mouse. *J Invest Dermatol.* 2003;120:128–134.
- Kim EH, Kim YC, Lee ES, et al. The vascular characteristics of melasma. *J Dermatol Sci.* 2007;46:111–116.
- Kang YA, Choi HR, Na JI, et al. Copper-GHK increases integrin expression and p63 positivity by keratinocytes. *Arch Dermatol Res.* 2009;301:301–306.

15. Choi HR, Kang YA, Na JI, et al. Oligosaccharides of hyaluronic acid increased epidermal cell stemness by modulation of integrin expression. *J Cosmet Dermatol*. 2012;11:290–296.
16. Park SH, Kim DS, Park SH, et al. Inhibitory effect of p-coumaric acid by *Rhodiola sachalinensis* on melanin synthesis in B16F10 cells. *Pharmazie*. 2008;63:290–295.
17. Na JI, Choi SY, Yang SH, et al. Effect of tranexamic acid on melasma: a clinical trial with histological evaluation. *J Eur Acad Dermatol Venereol*. 2013;27:1035–1039.
18. Du B, Bian Z, Xu B. Skin health promotion effects of natural beta-glucan derived from cereals and microorganisms: a review. *Phytother Res*. 2014;28:159–166.
19. Khoshnoodi J, Pedchenko V, Hudson BG. Mammalian collagen IV. *Microsc Res Tech*. 2008;71:357–370.
20. Varani J, Spearman D, Perone P, et al. Inhibition of type I procollagen synthesis by damaged collagen in photoaged skin and by collagenase-degraded collagen in vitro. *Am J Pathol*. 2001;158:931–942.
21. Quan T, Fisher GJ. Role of Age-Associated Alterations of the Dermal Extracellular Matrix Microenvironment in Human Skin Aging: a Mini-Review. *Gerontology*. 2015;61:427–434.

How to cite this article: Chae JB, Yang SH, Byun SY, Choi H-R, Shin J-W, and Park K-C. The effects of hydroporation on melasma with anti-aging cocktail. *J Cosmet Dermatol*. 2017;16:e15–e20. doi:10.1111/jocd.12313.