

Significant improvement in crow's feet after treatment with Jet-M and a mixed solution of copper-GHK, oligo-hyaluronic acid, rhodiolar extract, tranexamic acid, and β -glucan (GHR formulation)

Sang-Young Byun, Je-Byeong Chae, Jung-Im Na & Kyoung-Chan Park

To cite this article: Sang-Young Byun, Je-Byeong Chae, Jung-Im Na & Kyoung-Chan Park (2016) Significant improvement in crow's feet after treatment with Jet-M and a mixed solution of copper-GHK, oligo-hyaluronic acid, rhodiolar extract, tranexamic acid, and β -glucan (GHR formulation), Journal of Cosmetic and Laser Therapy, 18:5, 293-295, DOI: [10.3109/14764172.2016.1157367](https://doi.org/10.3109/14764172.2016.1157367)

To link to this article: <http://dx.doi.org/10.3109/14764172.2016.1157367>



Accepted author version posted online: 11 Apr 2016.
Published online: 26 May 2016.



Submit your article to this journal [↗](#)



Article views: 53



View related articles [↗](#)



View Crossmark data [↗](#)

CASE REPORT

Significant improvement in crow's feet after treatment with Jet-M and a mixed solution of copper–GHK, oligo-hyaluronic acid, rhodiolar extract, tranexamic acid, and β -glucan (GHR formulation)

Sang-Young Byun, Je-Byeong Chae, Jung-Im Na, and Kyoung-Chan Park

Department of Dermatology, Seoul National University College of Medicine and Seoul National University Bundang Hospital, Seongnam, Korea

ABSTRACT

Jet-M (Tav-Tech Ltd., Israel) is an instrument for skin resurfacing. When it sprays microdroplets of solution or shoots air on the skin, exfoliation and stretching of superficial layers can occur. Thus, it will increase percutaneous absorption of vitamins and other cosmetic agents. A cosmetic preparation containing copper–glycyl-L-histidyl-L-lysine, oligo-hyaluronic acid, rhodiolar extract, tranexamic acid, and β -glucan was used with Jet-M in one patient.

Anesthesia was not administered and there was no pain during the treatment. A male aged 59 years was treated once a week for 12 weeks. In the clinical photographs, wrinkles around the treated eye were greatly decreased. Skin biopsies were taken from treated and untreated areas. Hematoxylin and eosin and Masson's trichrome staining showed increased collagen production in the upper dermis. On the other hand, collagen IV production was slightly increased. Fibrillin-1 and procollagen type 1 were greatly increased and tropoelastin was also increased. There was no adverse effect during and after treatment.

ARTICLE HISTORY

Received 3 June 2015
Accepted 11 January 2016

KEYWORDS

Jet-M; skin resurfacing; laser; crow's feet; wrinkles

Introduction

Jet-M (Tav-Tech Ltd., Yehud, Israel), originally developed as JetPeel-2 in 2005, can be used for skin resurfacing (1). Occurrences of exfoliation and stretching of the superficial skin can occur from the spraying of air and microdroplets of the solution. Jet-M, an improved version of JetPeel-2, embeds a compressor unit. In general, Jet-M and other models of JetPeel family can deliver liquid solutions into the dermis (2). Flow of air is being accelerated to a subsonic speed, and the force from turbulence breaks the liquid into microdroplets (2). Paash et al. (2) suggested the term “hydroporation,” which worked based on high velocity flow of air and droplets, small size of droplets (5–20 micron), and stretch-open microchannels. In summary, key functions of Jet-M and other models of JetPeel are exfoliation and transdermal delivery (hydroporation).

One patient was treated with Jet-M and a cosmetic preparation containing copper–glycyl-L-histidyl-L-lysine (GHK), oligo-hyaluronic acid, rhodiolar extract, tranexamic acid, and β -glucan (GHR formulation). This report was approved by the institutional review board of Seoul National University Bundang Hospital (B-1504/294-701).

Case presentation

A 59-year-old male was treated once a week for 12 weeks. Anesthesia was not necessary, and there were no pain and adverse effects. First, for peeling, air and 3cc of sterile saline

were shot through 3-nozzle spray, at a distance of 1 cm from the skin. Then, the left and right sides of the face were treated by air/1cc of GHR formulation and air/1cc of normal saline, respectively. The moving speed of handpiece was 2 cm/s and the working pressure was 95psi.

Before and after the treatment, a photograph was taken. The results showed that there was a significant improvement in the crow's feet of the treated side (Figure 1a,b). After a 12-week treatment session, skin biopsies were taken from both sides of the face. There were significant differences between the treated and untreated areas. Hematoxylin and eosin and Masson's trichrome staining showed significant collagen production in the upper dermis and around the hair follicle (Figure 2a–d). Confocal microscopic findings also showed significant changes. There was no significant difference in the expression of collagen type IV. However, expressions of fibrillin and procollagen type 1 were greatly increased in the upper dermis, and expression of tropoelastin was also increased in the upper dermis (Figure 2e–h).

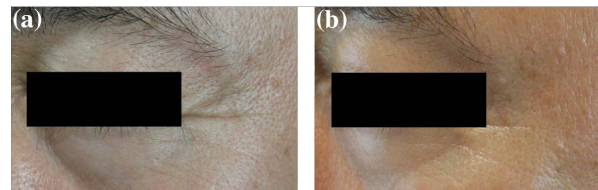


Figure 1. Improvement of crow's feet after 12 treatments. (a: before, b: after).

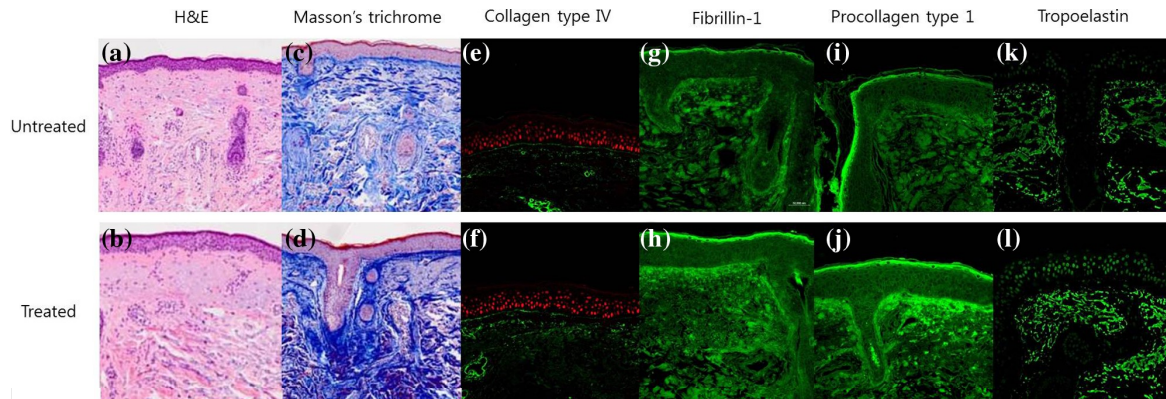


Figure 2. H&E staining (a, b), Masson's trichrome staining (c, d), and confocal microscopic examination with collagen type IV (e, f), fibrillin-1 (g, h), procollagen type 1 (i, j), and tropoelastin (k, l) in the untreated and treated sites. H&E and Masson's trichrome staining showed a significant increase in collagen production. Expressions of fibrillin-1 and procollagen type 1 were greatly increased in the upper dermis, and that of tropoelastin was also increased in the upper dermis.

Discussions

JetPeel was developed as a device for cosmetic resurfacing of the facial skin (1). It can produce a subsonic flow that accelerates the solution droplets to approximately 200 m/s through specialized nozzles (1). This power can gently exfoliate the skin, and additional layers of the upper dermis can be removed as set by the operator (1). Golan et al. (1) reported that it is a safe, accurate, and versatile instrument (1). Over the years, various models of JetPeel were developed in order to meet practitioner's needs. Contrary to the original models, such as JetPeel and JetPeel-2, which use O₂/CO₂ gas cylinder as the pressure source, Jet-M uses an embedded compressor as the pressure source.

In literature, there are several reports that describe the effects of series of these instruments. In 2011, Iannitti et al. (3) reported that JetPeelTM-3-mediated anesthesia was superior to EMLA cream administration ($p < 0.001$). In 2014, Iannitti et al. (4) also reported that JetPeelTM-3 can efficiently be used to treat primary palmar, plantar, and axillary hyperhidrosis by delivering both anesthetic and BTX-A at the same time (3). Since a compressor system was used in this study, similar results can be anticipated using the Jet-M unit.

In this study, the effects of a cosmetic preparation that contained copper-GHK, oligo-hyaluronic acid, rhodiolar extract, tranexamic acid, and β -glucan (GHR formulation), combined with Jet-M, were tested. GHK spontaneously forms a complex (copper-GHK) with copper ion through its high affinity, and copper-GHK heals wounds and repairs tissues by boosting collagen synthesis (5). Oligo-hyaluronic acid was reported to enable the epidermis to become thicker in the skin equivalent model (6). *p*-Coumaric acid is one of the components of rhodiolar extract, and it has a significant inhibitory effect on melanogenesis through competitive inhibition activity between *p*-coumaric acid and tyrosine (7). Tranexamic acid can reduce the epidermal pigmentation by decreasing the vascularity and mast cell numbers in the melasma treatment (8). β -Glucan enhances general skin health by acting as antioxidant, anti-wrinkling, anti-ultraviolet light, wound healing, and moisturizing agents (9). Hence, antiaging and hypopigmenting effect is anticipated if GHR formulation can be delivered into the skin. In this study, 3-nozzle tips were used to deliver GHR

formulation. As described, anesthesia was not necessary and this power did not induce any injury to the skin. Surprisingly, Jet-M with GHR formulation significantly improved skin aging. Fine wrinkle at the corner of the eye (crow's feet) decreased significantly after 12 consecutive infiltrations (Figure 1). In addition, histologic findings clearly showed that collagen production is dramatically increased. Furthermore, synthesis of fibrillin-1 and procollagen type 1 is also significantly increased (Figure 2). These findings suggested that Jet-M with GHR formulation will be a good and safe strategy for antiaging of the skin and will be very useful as the treatment for fine wrinkles. To facilitate the versatility and flexibility of treatments, various models of JetPeel can be used with an entire range of specialized handpieces. Besides the standard "triple nozzle" handpiece used in this study, there are "single nozzle" handpieces for localized treatments, "double nozzle" handpieces for hair and scalp treatments, and other specialized versions of handpieces. A further study is necessary to confirm the effects and extend its indication.

Funding

This study was supported by a grant from the Korean Health Technology R&D Project, Ministry of Health and Welfare, Republic of Korea (grant number: HN14C0094).

Declaration of interest

The authors report no conflicts of interest. The authors alone are responsible for the content and writing of the paper.

References

- Golan J, Hai N. JetPeel: a new technology for facial rejuvenation. *Ann Plast Surg.* 2005;54:369–374.
- Paasch U. Epidermal and dermal histological characteristics in response to hydroporation. *Kosmetische Medizin* 515 2015.
- Iannitti T, Capone S, Palmieri B. Short review on face rejuvenation procedures: focus on preoperative antiseptic and anesthetic delivery by JetPeel-3 (a high pressure oxygen delivery device). *Minerva chir.* 2011;66:1–8.
- Iannitti T, Palmieri B, Aspiro A, Di Cerbo A. A preliminary study of painless and effective transdermal botulinum toxin A delivery by jet

- nebulization for treatment of primary hyperhidrosis. *Drug Des Devel Ther* 2014;8:931–935.
5. Kang YA, Choi HR, Na JI, Huh CH, Kim MJ, Youn SW, et al. Copper-GHK increases integrin expression and p63 positivity by keratinocytes. *Arch Dermatol Res*. 2009;301:301–306.
 6. Choi HR, Kang YA, Na JI, Huh SY, Huh CH, Kim KH, Park KC. Oligosaccharides of hyaluronic acid increased epidermal cell stemness by modulation of integrin expression. *J Cosmet Dermatol*. 2012;11:290–296.
 7. Park SH, Kim DS, Park SH, Shin JW, Youn SW, Park KC. Inhibitory effect of p-coumaric acid by *Rhodiola sachalinensis* on melanin synthesis in B16F10 cells. *Die Pharmazie* 2008;63:290–295.
 8. Na JI, Choi SY, Yang SH, Choi HR, Kang HY, Park KC. Effect of tranexamic acid on melasma: a clinical trial with histological evaluation. *J Eur Acad Dermatol Venereol*. 2013;27:1035–1039.
 9. Du B, Bian Z, Xu B. Skin health promotion effects of natural beta-glucan derived from cereals and microorganisms: a review. *Phytother Res*. 2014;28:159–166.